

Corneal collagen cross-linking (CXL) for the treatment of melting keratitis in cats and dogs: a pilot study

Bernhard M. Spiess,* Simon A. Pot,* Marion Florin*¹ and Farhad Hafezi†

*Equine Department, Vetsuisse Faculty, University of Zurich, Winterthurerstrasse 260, CH-8057 Zurich, Switzerland; and †Division of Ophthalmology, Department of Clinical Neurosciences, University Hospitals of Geneva, Rue Alcide-Jentzer 22, CH-1211 Geneva 14, Switzerland

Address communication to:

F. Hafezi

Tel.: +41 22 382 83 60

Fax: +41 22 382 84 33

e-mail: farhad.hafezi@hcuge.ch

B.S. and S.P. have contributed equally to this study.

¹Present address: Augen Vet, Animal Eye Service, Kleintierklinik Breitensee, Breitenseer Strasse 16, 1140 Vienna, Austria.

Abstract

Objective UV-A/riboflavin cross-linking (CXL) of corneal collagen fibers is an established, highly promising therapy for corneal melting in physician-based ophthalmology. A prospective pilot study was conducted to demonstrate proof of principle of this novel method for the treatment of melting corneal ulcers in dogs and cats.

Procedures After obtaining owner consent, CXL was performed in three cats and three dogs with corneal melting, which either affected the entire corneal surface or was resistant to conventional antibiotic and anticollagenolytic therapy, and affected parts or all of the corneal surface. Medical therapy was continued in all patients. The available follow-up ranged from 2 to 22.5 months and involved slit-lamp examination, fluorescein staining, and photographic documentation during all rechecks.

Results Surgical stabilization of the cornea was not necessary in any case, because progression of corneal melting was arrested in all cases within 1–20 days of CXL treatment. Corneal re-epithelization occurred within 7–40 days in all eyes. At 40 days after CXL, all eyes presented a quiescent corneal state without signs of active inflammation and with beginning scar formation. The complications observed in three of the six animals included a corneal sequestrum, superficial corneal stromal pigmentation, and bullous keratopathy.

Conclusions This study shows the feasibility of CXL to treat progressive corneal melting in veterinary patients. CXL may represent a cost-efficient and safe alternative therapy in the treatment for corneal melting in veterinary ophthalmology. More investigations comparing the effectivity and complication rate of CXL to those of standard medical treatment are necessary.

Key Words: cornea, cross-linking, keratomalacia, riboflavin, UV-A, veterinary

INTRODUCTION

Cross-linking (CXL) was developed for the treatment of primary and secondary corneal ectatic diseases: keratoconus, pellucid marginal degeneration, and iatrogenic keratectasia.^{1–4} These conditions are all characterized by a distinct decrease in corneal biomechanical stability. Between 2003 and 2007, additional indications for CXL were introduced: bullous keratopathy, early Fuchs' dystrophy, and the treatment of noninfectious and infectious corneal melting.^{5–11}

Corneal melting is caused by the release of endogenous and exogenous collagenolytic matrix metalloproteinase (MMP) enzymes and an imbalance between these proteolytic enzymes and the proteinase inhibitors present in the cornea and precorneal tear film.^{12,13} An infection often

drives the inflammatory state responsible for corneal melting, but cannot always be demonstrated.¹⁴ Infectious melting keratitis in people represents a serious and vision-threatening condition, especially in the developing countries.^{15–18} In the veterinary field, infectious melting keratitis is an even more common condition and occurs with relative frequency, especially in predisposed breeds.^{19,20} There are few corneal pathogens that are directly associated with primary corneal infections in veterinary medicine.^{21–24}

Infectious melting keratitis is typically caused by secondary bacterial or fungal corneal infections. Secondary infections are usually facilitated by prior problems that weaken the cornea's anatomic barriers and physiologic defenses such as low corneal sensation, quantitative and qualitative tear film deficiencies, exposure keratitis,

trauma, eyelid abnormalities. Such prior problems, topical medications, and systemic immune-mediated disease may also lead to melting in the absence of infection by affecting the balance of the healing response through the production of collagenolytic agents by resident and inflammatory cells.^{25–28}

Aggressive treatment with topical antimicrobials to battle a potential infection and with anticollagenases to directly counter collagenolysis is indicated to stop progression of the melting process.^{12,14} The results of medical treatment are variable. Several factors including the often advanced state of the disease at which veterinary patients are presented to the ophthalmologist, inability of owners to adequately follow drug therapy, antimicrobial drug resistance of pathogens²⁹ and problems with patient compliance can negatively influence the course of the disease. In a significant number of cases, corneal melting leads to progressive ulceration and even perforation, necessitating globe stabilizing, tectonic surgery, or enucleation. Some clinicians and owners might even feel forced to elect euthanasia over treatment in extreme cases.^{14,30}

Natural collagen cross-links consist of covalent bonds between the amino side chains of the collagen fibers and are one of the physiological principles that assure the biomechanical stability of the cornea. The technique of corneal collagen cross-linking with riboflavin and UV-A irradiation (CXL) is a new treatment modality that was introduced to clinical use in humans in 1999.⁴ Riboflavin (vitamin B2) acts as a photosensitizer when exposed to UV-A light with a wavelength at the riboflavin absorption peak of 370 nm. Free radicals introduce additional cross-links within and between collagen fibers in this process of photopolymerization, increasing the biomechanical stability of the human cornea to a depth of 330 μm .³ The biochemical stability of the cornea is increased by sterical hindrance of collagenase-binding sites and subsequent inhibition of the collagenolytic enzyme activity.³¹ Additionally, the free radicals induced by CXL directly damage and destroy microorganisms and lead to apoptosis of cells in the irradiated area.^{9,11,32–34}

The degree of efficacy and safety of CXL is dependent on the absorption of UV-A radiation by riboflavin-soaked corneal tissue, which makes the diffusion of riboflavin within the cornea and degree of riboflavin saturation of the superficial stroma crucial to CXL treatment.³⁵ Riboflavin diffuses throughout the entire corneal stroma and can also be detected in the anterior chamber with a slit-lamp. A standard CXL treatment protocol as described in the materials and methods section of this paper led to keratocyte death up to a depth of approximately 300 μm in rabbits. The depth of keratocyte loss was directly and positively correlated with the UV-A irradiance level.³⁴ No observable toxic effects were present beyond 300 μm . A similar CXL depth penetration was demonstrated with *in vivo* confocal microscopy in a clinical study in humans.³⁶ This maximal treatment depth gave rise to the concept of

riboflavin shielding, an effect that protects all the structures at deeper levels such as the corneal endothelium, iris, lens epithelium, lens fibers, and the retina, which are theoretically exposed to a safe level of UV radiation.³⁵ Histologic damage to endothelial cells was demonstrated only when the normal UV radiation dose (UV irradiance of 3 mW/cm^2) was exceeded at least twofold in 400- μm -thick rabbit corneas.³⁷ As UV radiation travels through the corneal stroma, photons are continuously absorbed by riboflavin molecules: decreasing the number of photons, the deeper the irradiation penetrates the tissue. The overall energy arriving at the endothelium is thus lowered, resulting in UV-A irradiance at the level of the endothelium that is less than half of the endothelium's damage threshold of 0.36 mW/mm^2 .³⁵ The combination of riboflavin saturation of the corneal stroma and a minimal corneal stromal thickness of more than 300 μm during treatment theoretically guarantees the safety of CXL. This has led to the recommendation that CXL should only be performed in physician-based ophthalmology if the total corneal thickness measures at least 400 μm .³⁸

During the last 5 years, several groups have published studies in humans where CXL was used as an adjuvant treatment in cases where medical therapy had failed to control infectious melting keratitis. In all cases published, CXL led to an arrest of progression of infectious melting.^{7,8,39–42}

To our knowledge, there are no published descriptions of the use of CXL in veterinary ophthalmology. This is a pilot study that investigates and reports the potential effectiveness of CXL as described for use in humans for the treatment of keratitis and stromal melting in three cats and three dogs.

MATERIALS AND METHODS

Animals

Three cats and three dogs with unilateral progressive corneal melting were included in this interventional prospective study. All treatments were performed at the veterinary clinical teaching hospital of the Veterinary (Vetsuisse) Faculty of the University of Zurich, Switzerland, after obtaining owner consent. All procedures conformed to the ARVO Statement for the Use of Animals in Ophthalmic and Vision Research and were in accordance with institutionally approved animal protocols. Table 1 summarizes the clinical and ocular characteristics of the animals. Table 2 summarizes the medical treatment given before referral, between referral and CXL treatment, and after CXL treatment.

Pretreatment examination

Pretreatment analysis included slit-lamp examination, fluorescein staining, photography, and corneal culture and sensitivity testing. Culture and sensitivity samples were collected from all cats and one dog (Dog2). Although all

Table 1. Signalment, pre- and post-CXL-treatment patient characteristics

Patient	Breed	Age (years)	Diameter of infiltrate prior to CXL (mm)	Maximal ulcer depth prior to CXL (%)	Result of bacteriology	Treatment prior to referral (days)	Treatment prior to CXL (days)*	Stabilization stroma after CXL within (days) [†]	Complete epithelial closure after (days) [‡]	Follow-up (months)
Cat1	European short hair	8	5 × 4	15–20	No growth	0	15	2	18	17.5
Cat2	European short hair	11	5 × 7	50	No growth	3	1	4	7	22.5
Cat3	European short hair	13	11 × 11	75	No growth	4	1	12	15	14
Dog1	Pug	6	5 × 5	50	No bacteriology	0	1	1	13	5
Dog2	Pug	7	11 × 13	50	No growth	2	0	1	40	3
Dog3	Samoyed	13	8 × 7	Superficial ulcer	No bacteriology	30	2	20	30	2

*Treatment prior to CXL refers to the duration of treatment (in days) received after referral to the veterinary clinical teaching hospital of the Veterinary (Vetsuisse) Faculty of the University of Zurich, Switzerland, but before undergoing CXL. [†]All animals were treated with topical and/or systemic collagenase inhibitors at least until the corneal stroma was judged to be stable, based on the semi-objective evaluation of stromal stability/melting activity as described in the Materials and Methods.

[‡]All animals were treated with topical antibiotics until complete epithelial closure had occurred.

Table 2. Summary of medical treatment given before and after CXL treatment

Patient	Medical treatment		
	Prior to referral	Referral – CXL	Post-CXL
Cat1	Tobramycin	Ofloxacin 0,3% Q1-6H Oxytetracycline 1% Q4-6H Atropine 1% once daily Meloxicam*	Oxytetracycline 1% Q4-6H K-EDTA 0,36% Q6H Meloxicam*
Cat2	Neomycin/polymyxin/bacitracin	Tobramycin 0,3% Q2-4H Oxytetracycline 1% QID Serum Q2-4H K-EDTA 0,36% Q2-4H Artificial tear gel Q2-4H Doxycycline [†] Meloxicam*	L-lysine 500 mg BID Tobramycin 0,3% Q2-4H Oxytetracycline 1% QID Serum Q2-4H K-EDTA 0,36% Q2-4H Artificial tear gel Q2-4H Doxycycline [†] Meloxicam*
Cat3	Ciprofloxacin	Oxytetracycline 1% QID K-EDTA 0,36% Q4H Serum Q4H Buprenorphine 0.007 mg/kg QID	Oxytetracycline 1% QID Ofloxacin 0,3% Q4H K-EDTA 0,36% Q4H Doxycycline [†] Buprenorphine 0.007 mg/kg QID
Dog1		Neomycin/polymyxin/gramicidin Q4H Oxytetracycline 1% QID K-EDTA 0,36% Q4H Atropine 1% once daily	Neomycin/polymyxin/gramicidin Q4H Oxytetracycline 1% QID K-EDTA 0,36% Q4H Atropine 1% once daily
Dog2	Tobramycin/dexamethasone Ciprofloxacin Atropine Vitamin A Dorsolamide (topical) Meloxicam (oral)		Ofloxacin 0,3% Q2-4H Oxytetracycline 1% TID Serum Q2-4H K-EDTA 0,36% Q2-4H Doxycycline [†]
Dog3	Neomycin/polymyxin/bacitracin Chloramphenicol Dexamethasone (topical)	Oxytetracycline 1% TID K-EDTA 0,36% QID	Oxytetracycline 1% TID K-EDTA 0,36% QID 5% NaCl ointment QID

*Meloxicam was prescribed once daily at 0.1 mg/kg on day 1 and 0.05 mg/kg afterward. [†]Doxycycline was prescribed at 5 mg/kg BID on day 1, once daily afterward.

animals had been treated with topical antibiotics prior to collection of the culture samples, culture and sensitivity testing was abandoned in two dogs (Dog1 and Dog3) due

to the previously initiated antibiotic therapy. The diagnosis of corneal melting was based on a subjective evaluation of stromal stability/melting activity, including the presence

of cellular infiltrates, the perceived stability of the stroma, the presence of changes in corneal contour and ulcer depth, and the presence of malacic corneal material in the ulcer area. Cellular infiltrates were present in all affected corneas, and although corneal thickness could not be measured reliably over the area of the infiltrates, slit-lamp examination showed the loss of corneal stroma in all cases (Table 1).

Cat1, an eight-year-old male castrated European Shorthair, presented with a history of bilateral, chronic, intermittent eye problems, which had been responsive to topical tobramycin treatment according to the owner. No further medications were given prior to referral. Upon examination, a corneal ulcer with yellow cellular infiltrates and 10% loss of stroma was observed in the left eye (OS). No further (peri)ocular abnormalities that might account for the melting keratitis were observed. Between referral and CXL, the cat was treated with topical ofloxacin and atropine and oral meloxicam. Ofloxacin treatment was discontinued and topical oxytetracycline started 2 days before the CXL procedure due to progressive deepening of the ulcer. CXL was performed 15 days after initial presentation because of continued deepening of the ulcer (progression to 15–20% stromal loss). Topical K-EDTA was added to the treatment regimen after CXL to help control collagenolysis.

Cat2, an 11-year-old male castrated European Shorthair, presented with a rapidly deteriorating opacity and blepharospasm of the right eye (OD), despite the treatment with neomycin/polymyxin/bacitracin ophthalmic ointment for 3 days prior to referral. A corneal ulcer with 40% stromal loss, cellular infiltrates, and a malacic center was observed. No further (peri)ocular abnormalities that might account for the melting keratitis were observed. Between referral and CXL, topical treatment with tobramycin, oxytetracycline, serum, K-EDTA and artificial tear gel and systemic treatment with doxycycline and meloxicam was initiated. CXL was performed the next day due to progressive melting in the center of the ulcer (progression to 50% stromal loss). Medical treatment was continued afterward.

Cat3, a 13-year-old female spayed British Shorthair, presented with a progressively deteriorating opacity and blepharospasm OD, despite the treatment with ciprofloxacin eye drops multiple times per day for four days prior to referral. On examination, dense cellular infiltrates, malacic corneal stroma, and stromal loss were observed across the entire cornea OD. The exact ulcer depth was variable across the ulcer, but not recorded at this time-point. A mild conjunctival hyperemia, presence of thin superficial mid-peripheral corneal ghost vessels, and mild superficial corneal stromal fibrosis were observed OS. A tentative diagnosis of previous FHV-1-induced keratitis was made. No further (peri)ocular abnormalities that might account for the melting keratitis OD were observed. Between referral and CXL, topical treatment with oxytetracycline,

K-EDTA and serum and systemic treatment with buprenorphine was initiated. CXL was performed the next day due to progressive deepening of the corneal defect (progression to 75% stroma loss at the deepest point, observed by the same examiner as the previous day) and the extension of the lesion. Topical serum was discontinued and topical ofloxacin and systemic doxycycline were started shortly after the CXL treatment because of poor patient compliance, concerns regarding the sterility of the serum, and continued instability of the mid-peripheral inferior cornea.

Dog 1, a six-year-old male Pug, presented with a history of distichia removal prior to referral. The additional history and medical treatment prior to referral were unknown. A corneal ulcer with 50% stromal loss and mild cellular infiltrates were observed OS. Macrophthalmos, lagophthalmos, nasal lower eyelid entropion and trichiasis, and nasal conjunctival and superficial corneal pigmentation were observed in both eyes (OU). No further (peri)ocular abnormalities that might account for the melting keratitis OS were observed. Between referral and CXL, topical treatment with neomycin/polymyxin/bacitracin, oxytetracycline, K-EDTA and atropine was initiated. CXL was performed after one day of treatment because of progressive ulceration and the appearance of additional stromal ulcers despite the medical therapy. Medical treatment was continued after CXL.

Dog2, a seven-year-old female spayed Pug, presented with a two-day history of blepharospasm and progressive opacification OD. Initially, the eye was treated with topical tobramycin/dexamethasone and atropine and with systemic meloxicam. On day two, a fluorescein-positive defect was observed, tobramycin/dexamethasone was discontinued, and topical ciprofloxacin, trusopt, and vitamin A were added to the treatment regimen by the referring veterinarian immediately prior to referral. On examination, the entire central and mid-peripheral superficial 50% of the stromal layer was moveable relative to the underlying deeper stroma using a cotton-tipped applicator, and the corneal surface had started to deform, had lost its normal regular curvature and was protruding over the lower eyelid margin. Relatively mild macroblepharon, lagophthalmos, nasal lower eyelid entropion, and trichiasis were observed OU, in addition to nasal conjunctival and superficial corneal pigmentation. No further (peri)ocular abnormalities that might account for the melting keratitis OD were observed. CXL was performed immediately and treatment with topical ofloxacin, oxytetracycline, serum and K-EDTA and systemic doxycycline was initiated.

Dog3, a 13-year-old female spayed Samoyed, presented with a one-month history of corneal problems OD. The owner had initiated treatment with topical neomycin/polymyxin/bacitracin and dexamethasone and had switched to topical chloramphenicol 1 week prior to presentation because of increased opacification of the cornea. A corneal ulcer with minimal stromal loss, associated malacic

stroma, and cellular infiltrates was observed OD. No further (peri)ocular abnormalities that might account for the melting keratitis OD were observed. CXL was performed after a two-day period of medical therapy with topical oxytetracycline and K-EDTA with no improvement. Medical therapy was continued after CXL.

Medical therapy with topical antibiotics and anticolagenases was continued in all patients after CXL treatment because discontinuation of medical treatment was judged unethical in light of the unknown efficacy of CXL treatment in dogs and cats. Table 2 contains a comprehensive view on the medical treatment of the patients in the study.

The CXL procedure

All procedures were performed under standard general, isoflurane maintained, inhalation anesthesia (Fig. 1). After the application of a topical anesthetic (oxybuprocaine 0.4% or tetracaine 0.1% drops) to the affected corneas, the corneal epithelium was removed with a cotton-tipped applicator within a 7- to 9-mm-diameter zone, depending on the size of the infiltrate. A cotton-tipped applicator was also used for a subjective tactile assessment of stromal stability. The area containing the cellular infiltrate carried no epithelium due to the inflammatory and melting process. After inserting a lid speculum, isoosmolar 0.1% riboflavin drops were administered every 3 min for 30 min. The riboflavin drops were prepared immediately before the treatment by mixing 0.5% aqueous riboflavin solution (vitamin B₂; Streuli, Uznach, Switzerland) and a sterile 20% dextran T-500 solution. Successful penetration of riboflavin through the corneas was confirmed by visualizing the riboflavin in the anterior chamber with slit-lamp biomicroscopy. Then, the corneas were irradiated for 30 min with 365-nm wavelength ultraviolet A light (UV-A), with an irradiance of 3 mW/cm² (UV-X; Peschke

Meditrade, Cham, Switzerland). The diameter of irradiation was either 9, 10, or 11 mm depending on the size of the infiltrate and particular care was taken not to irradiate the corneal limbus as this area contains the corneal epithelial stem cells that are crucial to re-epithelialization of the corneal surface. During the 30-min irradiation period, the cornea was moistened every 3 min with isoosmolar 0.1% riboflavin solution. The UV light was focused on the corneal surface at a distance of 5 cm. The distance was measured in every patient. The Köhler's optics in the UV device minimize the variation in UV intensity between 3 and 7 cm of distance to the eye. CXL was performed in the presence of a certain risk of UV-induced cytotoxicity to the endothelium in corneas demonstrating significant loss of corneal stroma.

Post-treatment follow-up

The available follow-up ranged from 2 to 22.5 months and included slit-lamp examination, fluorescein staining, and photographic documentation during all re-examinations.

Post-treatment examinations were performed at day 1 and days 4, 7, 14, and 28 after surgery and at various times during the long-term follow-up.

RESULTS

Cross-linking was used in three cats and three dogs with unilateral severe corneal melting. Table 1 summarizes the pre- and postoperative characteristics of all animals: All cases presented with active corneal melting of unknown cause, as described in the Materials and Methods section.

Based on the subjective evaluation of stromal stability/melting activity as described in the Materials and Methods section (including the presence of cellular infiltrates, the perceived stability of the stroma via tactile assessment with a cotton-tipped applicator, the presence of changes in corneal contour and ulcer depth, and the presence of malacic corneal material in the ulcer area), the stroma was judged to be stable between 1–20 days post-CXL in all patients. A stable stroma was observed much earlier in four of six cases: between 1–2 days after CXL in three cases (Cat1, Dog1, and Dog2) and in 4 days in another case (Cat2). CXL as well as the post-treatment period was uneventful in Cat1, Cat2 (Fig. 2 a–d) and Dog1, and the clinical signs of corneal melting were markedly reduced immediately after CXL (see Table 1). In Dog2 (pug, Fig. 3 d–f), in which keratomalacia affected the superficial stroma of the entire central and mid-peripheral cornea, the stroma was judged to be stable on the first day after CXL. However, this patient did develop significant superficial pigmentation during the second month after the procedure. The treated cornea of cat number 3 (Fig. 3 a–c) developed a corneal sequestrum within the early post-treatment period and showed spontaneous extrusion within 1 month of development. From day 6 on, the stromal instability was confined

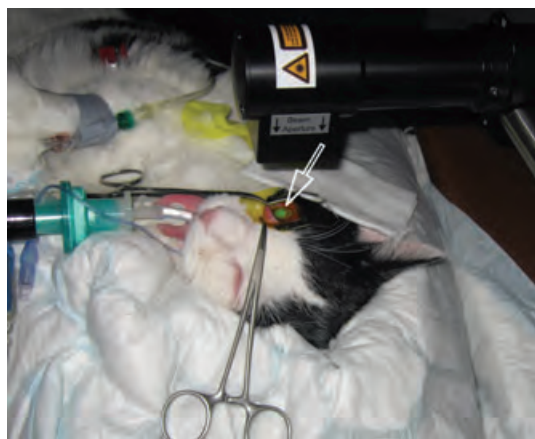

Figure 1. Clinical setup of the CXL procedure under general anesthesia. The irradiation source is placed at a distance of approximately 5 cm to the eye. The cornea is soaked with riboflavin that shows fluorescence when irradiated at 365 nm (arrow).

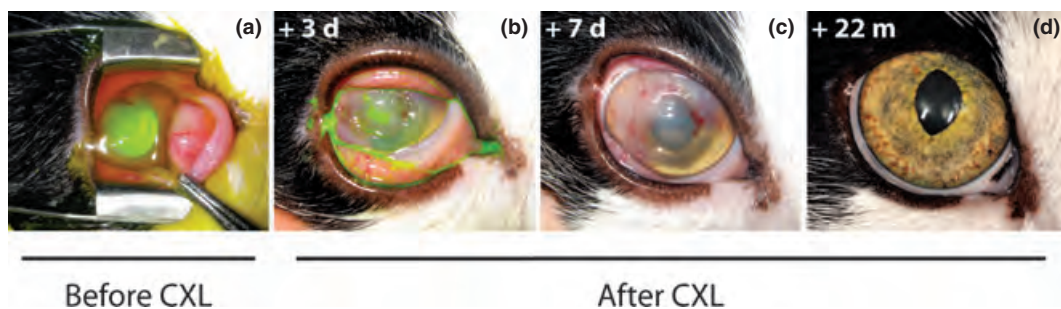


Figure 2. Pre- and post-CXL-treatment photographs of the ocular adnexa and cornea of Cat2 (a-d). In this patient, the healing process was uncomplicated and the long-term outcome excellent. The epithelial defect had closed and the outline of an area with significant loss of stroma was visible at day 7 (c). At 22 months after CXL treatment, the cornea showed some thinning and minimal superficial stromal fibrosis at the previous ulcer site (d).

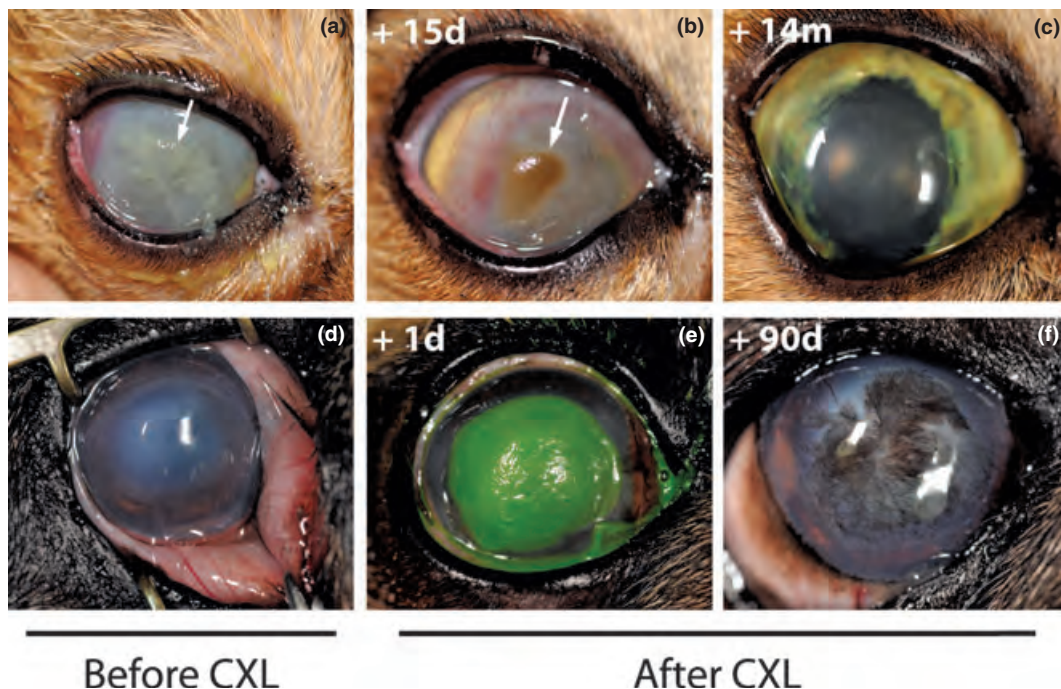


Figure 3. Pre- and post-CXL-treatment photographs of the ocular adnexa and cornea of Cat3 and Dog2. Cat3 (a-c): The entire corneal surface area was affected (a) and 75% of the stromal thickness had been lost at the spot where the ulcer was deepest. On day 15 after CXL treatment, a corneal sequestrum was diagnosed (b, white arrow). In retrospect, this sequestered area of cornea was clearly visible on the pictures taken at preceding examinations (see a, white arrow). After spontaneous extrusion of the sequestrum, the outcome was excellent, with some loss of corneal transparency due to moderate corneal fibrosis (c). Dog2 (d-f): In this pug, keratomalacia affected the superficial stroma of the entire central and mid-peripheral corneal surface. The superficial stroma was moveable relative to the underlying deeper stroma and the corneal surface had started to deform and lose the normal regular curvature (d). The stroma was judged to be stable on the first day after CXL (e). Slow, progressive re-epithelialization of the corneal surface was observed during further rechecks and significant superficial corneal pigmentation developed during the second month after surgery. No changes in pigmentation were observed afterward (f).

to the area beneath and immediately surrounding the developing corneal sequestrum, whereas the rest of the initial ulcer bed was stable from day 6 onwards. The stroma of the entire cornea was stable after 12 days. After spontaneous extrusion of the sequestrum, granulation tissue was observed in the underlying stroma. Complete stabilization of the corneal stroma was observed after 20 days in Dog3. The corneal edema that was present at initial presentation did not disappear during the initial healing stages, but

rather deteriorated despite the stabilization of the melting process. Bullous keratopathy and an epithelial erosion were observed at 6 weeks after CXL (3 weeks after the stroma had stabilized). The intensity of the corneal edema had decreased and the epithelial erosion closed after 2 weeks of topical treatment with 5% NaCl ointment. Signs of endothelial damage were only observed in Dog3. Complete closure of the corneal epithelium was observed in all cases between 7 and 40 days following CXL. Culture

and sensitivity tests were negative for all patients for which these were submitted (all cats and Dog2).

DISCUSSION

CXL is a technique that was initially developed for the treatment of progressive keratoconus in humans.^{2,4,43} Subsequently, the range of indications was expanded to post-LASIK ectasia,¹ bullous keratopathy,⁵ early Fuchs' dystrophy⁶ and, finally, infectious corneal melting.^{7–11} CXL has several mechanisms of action that make it an attractive adjunctive therapy for the treatment of corneal melting. Firstly, CXL increases the corneal rigidity and resistance to collagenases through changes in the tertiary structure of the collagen fibrils.^{31,44} Secondly, the UV-A-mediated photoactivation of riboflavin leads to reactive oxygen species-induced photooxidative DNA and RNA damage in viruses, bacteria, fungi, and protozoa.^{45,46} Martins *et al.* and Schrier *et al.* demonstrated the antimicrobial effect of CXL against a host of bacterial isolates *in vitro*.^{9,11} Interestingly, the combination of UV light and riboflavin has been used in transfusion medicine for decades to reduce the microbial and viral load in blood products.^{47–52} The use of CXL as sole treatment for experimentally induced *Fusarium* keratitis in a rabbit model was described in a recent paper.⁵³ The number of colony-forming units was significantly lowered and the clinically and histopathologically observed inflammatory changes were decreased in CXL-treated animals compared to untreated controls. Based on these results, CXL was considered to be a potentially useful adjuvant treatment, but not a likely primary treatment for fungal keratitis.

Following the proof of principle published in 2007, several groups have published studies in humans where CXL was used as an adjuvant treatment in cases where conventional therapy had failed to control infectious melting keratitis. In all cases published, CXL led to an arrest of progression of infectious melting and re-epithelialization.^{7,8,39–41} Indeed, in one study, CXL was successfully used as sole treatment, without the use of antibiotics, to stabilize corneas with confirmed (13 of 16 cases) and presumed (3 of 16 cases) bacterial keratitis.⁴² In light of these good clinical results, it is possible that CXL might one day become a primary treatment option for infectious corneal melting in humans. Following the initial basic research performed in previous animal studies,^{31,34,35,37,54} we have returned to the animal cornea with the present study with the aim to adapt the treatment protocol reported for use on human cases to the small animal cases included in this clinical study. The authors theorized that CXL treatment should lead to as positive a result in the clinical cases included in this study as the clinical outcomes reported in clinical studies in human subjects. Progression of corneal melting was arrested in all six cases and surgical stabilization of the cornea was not necessary in any of the cases presented in this study. These results

are in agreement with the current basic scientific and clinical literature cited above.^{7–9,11,31,39–41,44,53} CXL may therefore be a useful adjunctive therapy for the treatment of corneal melting in the veterinary field by shifting the delicate collagenase–anticollagenase balance in the cornea toward stability in certain patients and preventing a progression toward further uncontrolled corneal melting. CXL could not be evaluated as the sole primary treatment nor as a treatment for infectious corneal melting in the present study because the animals enrolled were treated with topical anticollagenolytic medication after CXL and the presence of infection could not be demonstrated in any of the cases. CXL as well as the post-treatment period was uneventful in three cases (Cat1, Cat2, and Dog1). The other three cases underwent an uneventful CXL procedure, but a corneal sequestrum, significant superficial pigmentation, and bullous keratopathy developed in the early post-treatment period in Cat3, Dog2, and Dog3, respectively. Nevertheless, although the post-treatment healing period was prolonged in Cat3 and Dog3, the long-term outcome was good in all three cases with complications. The corneal sequestrum observed in Cat3 might represent the result of abundant keratocyte apoptosis either caused by the CXL procedure itself or by the extensive keratomalacia covering the entire surface and up to 75% of the stromal thickness. Keratocyte apoptosis has previously been identified ultrastructurally in cases of feline sequestrum and a role for keratocyte apoptosis in sequestrum formation was hypothesized.⁵⁵ It is possible that the area of the cornea that later developed into a sequestrum had already begun the sequestration process, as in retrospect this area was already clearly visible in the pre-operative clinical images (see Fig 3 a). The two pugs included in this cases series (Dog 1 and Dog2) were diagnosed with macroblepharon, lagophthalmos, nasal lower eyelid entropion, and trichiasis, in addition to nasal conjunctival and superficial corneal pigmentation in OU. Chronic keratitis caused by keratoconjunctivitis sicca,⁵⁶ medial canthal trichiasis, lower nasal eyelid entropion, or macropalpebral fissure⁵⁷ is a known stimulus for the development of corneal pigmentation and can also be a predisposing factor for the development of melting keratitis, especially in brachycephalic breeds.¹⁴ Melting keratitis can itself lead to corneal pigmentation through the induction of corneal neovascularization, stromal inflammatory cell infiltration, and granulation tissue.¹⁴ Only one of the two pugs (Dog2) developed significant progression of the corneal pigmentation in the treated eye in the second month following CXL treatment. It is therefore not clear whether the ocular pathology or the performed CXL procedure or both were significant factors in the development of corneal pigmentation in this patient.

The presence of a poorly healing erosion combined with bullous keratopathy in the Samoyed dog (Dog3) was indicative of endothelial damage. Endothelial decompensation and bullous keratopathy can be caused by breed-

related endothelial dystrophy, iris-to-cornea persistent pupillary membranes, (surgical) trauma, anterior uveitis/endotheliitis, glaucoma, toxic damage to the endothelium, age-related endothelial degeneration, and melting keratitis.¹⁴ Endothelial dystrophy, iris-to-cornea persistent pupillary membranes, surgical trauma, and glaucoma were unlikely causes in this patient due to a lack of ophthalmic abnormalities consistent with these diagnoses and no history of prior ocular surgery. Prior external trauma, anterior uveitis/endotheliitis, and toxic damage to the endothelium could not be ruled out but did not seem likely due to a lack of a history of prior eye problems consistent with these diagnoses. The history of a poorly healing erosion and concurrent white opacity in the cornea and the patient's age suggested a combination of pre-existing age-related endothelial degeneration and melting keratitis as a likely cause for the clinical problems in Dog3.⁵⁸ A pre-existing age-related endothelial decompensation may have been subclinical at the time of initial presentation or may have been missed by the clinician due to the overlying edematous stroma with cellular infiltrates. Alternatively, the CXL procedure itself might have led to the endothelial damage. It is unclear how the CXL procedure would have led to endothelial damage in this particular patient. Because the observed pretreatment stromal loss was minimal (Table 1), the minimal thickness of 300–400 μm of riboflavin-saturated stroma needed to ensure shielding of the endothelium from radiation damage should have been present. Inadequate focusing of the UV lamp on the corneal surface and subsequent excessive radiation delivery to deeper structures, which has been reported as a potential cause,⁵⁹ also seems unlikely because the presence of Köhler's optics in the UV device minimizes the variation in UV intensity between 3 and 7 cm of distance to the eye. A second possible cause for CXL-induced endothelial cell damage is a decrease in corneal stromal thickness due to inadequate application of riboflavin drops to the eye and subsequent desiccation during the riboflavin saturation and/or CXL treatment period. Repeated application of riboflavin during the CXL treatment period is not only necessary to minimize corneal dryness during the procedure but also to avoid the effects of degradation of active riboflavin molecules caused by UV-A exposure. If riboflavin is not replenished during the CXL procedure, UV photon absorption will decrease and UV depth penetration will increase, potentially exposing the corneal endothelium to harmful levels of UV radiation.⁶⁰ However, inadequate riboflavin application was unlikely due to surgeon experience and strict adherence to the safety protocol dictating complete saturation of the corneal stroma with riboflavin, replenishment of riboflavin during the entire procedure, and a homogeneous 365-nm UV irradiation of 3 mW/cm^2 of cornea.

A minimal corneal stromal thickness of more than 300 μm must be present for effective shielding of the

endothelium and the deeper structures of the eye.^{34–37} However, corneal thickness could not be monitored during this study due to a lack of physical means to perform ultrasound pachymetry. A stromal loss of 50% was observed in 3 of 6 animals enrolled in this study (Cat2, Dog1, and Dog2), and Cat3 had a maximal ulcer depth of 75% of the total corneal thickness (Table 1). It is therefore likely that the deepest areas of the ulcers were at risk for CXL-induced endothelial damage. We decided to perform CXL in the presence of a certain risk of UV-induced cytotoxicity to the endothelium because intervention was indicated in the face of medical treatment failure and risk of spontaneous perforation. Conjunctival grafts typically are the preferred reconstructive surgical technique to stabilize a melting corneal ulcer, as these grafts provide tectonic, antimicrobial, and anticollagenase support through the provision of fibrovascular tissue in the ulcer site. However, permanent scarring can be a major disadvantage of conjunctival grafts.^{14,61,62} The size of the corneal defects in two of the patients (Cat3 and Dog2, Fig. 3) would have necessitated the use of either very large conjunctival pedicle flaps or 360 degree corneal grafts to cover the defects. Such grafts would likely have blinded the eyes. In this light, localized endothelial damage potentially caused by CXL was theorized to pose a lesser overall risk to sight and the fate of the eye. However, experimental studies in rabbits³⁷ have demonstrated that CXL-induced endothelial damage could have caused significant problems, including chronic corneal edema, breakdown of stroma, bullous keratopathy with recurring epithelial erosions, and decreased vision as a result of all of these abnormalities. This does not seem to be a common problem in clinical physician-based ophthalmology though.⁵⁹ Interestingly, none of the aforementioned four patients with 50% stromal loss or more (Cat2, Cat3, Dog1, and Dog2) developed any sign of damage to the endothelium. We theorize that the presence of corneal edema and/or infiltrates in the ulcer bed caused the stroma to swell, leading to a safe corneal thickness of more than 300 μm . Alternatively, the remaining endothelial cells in these patients may have been able to compensate for a relatively small CXL-induced endothelial cell loss.

Antimicrobial drug resistance of pathogens seems to be an increasing problem in veterinary ophthalmology.²⁹ The possibility that an infection could have played a role in some of our patients could not be excluded completely based on the fact that false-negative results are a disadvantage of swab testing.²⁰ The treatment of certain drug-resistant microorganisms may be facilitated by the direct antimicrobial effect of CXL.⁹

Despite the fact that half of the patients enrolled into this pilot study suffered complications during the post-treatment period, it was not clear whether these complications were due to the CXL procedure or merely the result of the disease process that was treated. CXL is not currently Food and Drug Administration (FDA) approved;

however, it is an accepted and approved method of treatment for people in most countries in Europe and other parts of the world. The use of CXL for various corneal ectatic diseases is currently under investigation to gain FDA approval in 21 completed and ongoing registered clinical trials (<http://clinicaltrials.gov/>). Although no specific safety reports have been published yet, a very low rate or absence of significant, sight-threatening complications has been reported in these and other published clinical trials in humans.^{4,63–67} To our knowledge, there are no papers describing the application of CXL in veterinary ophthalmology. Basic safety and efficacy data are lacking for dogs, cats, and horses, which are the most common species presented to veterinary ophthalmologists. Long-term complications and side effects of CXL treatment in domestic animals are not known, but major complications seem unlikely due to the low complication rates in humans. Theoretically, as long as riboflavin is allowed to saturate the corneal stroma, a homogeneous 365-nm UV irradiation of 3 mW/cm² is delivered and the irradiated cornea has a minimal thickness of 350–400 µm, CXL should be a safe procedure.³⁵

In conclusion, the medical management of corneal melting in veterinary ophthalmology can be challenging and demands a time-consuming therapy. Frequently, it is seriously hampered by the often advanced stage of the disease, relative therapy resistance, and reduced compliance. The results described in this pilot study suggest that CXL may represent a cost-efficient and valuable adjunctive therapy for corneal melting in the veterinary field.

The relatively low cost involved in acquiring the system, the low cost of treatment, and the ease of performing the procedure make CXL accessible to the veterinary market. However, CXL has the potential to do serious harm when used in unsuitable ways or situations. Further controlled, masked, prospective clinical studies comparing the efficacy and complication rate of CXL to those of traditional medical therapy without CXL are therefore needed in order to evaluate the safety of this promising treatment modality and to identify indications and contraindications for its use in veterinary patients.

DISCLOSURE

None.

REFERENCES

- Hafezi F, Kanellopoulos J, Wiltfang R *et al*. Corneal collagen crosslinking with riboflavin and ultraviolet A to treat induced keratectasia after laser in situ keratomileusis. *Journal of Cataract and Refractive Surgery* 2007; **33**: 2035–2040.
- Hafezi F, Mrochen M, Iseli HP *et al*. Collagen crosslinking with ultraviolet-A and hypoosmolar riboflavin solution in thin corneas. *Journal of Cataract and Refractive Surgery* 2009; **35**: 621–624. Epub 2009/03/24.
- Seiler T, Hafezi F. Corneal cross-linking-induced stromal demarcation line. *Cornea* 2006; **25**: 1057–1059.
- Wollensak G, Spoerl E, Seiler T. Riboflavin/ultraviolet-a-induced collagen crosslinking for the treatment of keratoconus. *American Journal of Ophthalmology* 2003; **135**: 620–627.
- Ehlers N, Hjortdal J. Riboflavin-ultraviolet light induced cross-linking in endothelial decompensation. *Acta Ophthalmologica* 2008; **86**: 549–551.
- Hafezi F, Dejica P, Majo F. Modified corneal collagen crosslinking reduces corneal oedema and diurnal visual fluctuations in Fuchs dystrophy. *British Journal of Ophthalmology* 2010; **94**: 660–661. Epub 2010/05/08.
- Iseli HP, Thiel MA, Hafezi F *et al*. Ultraviolet A/riboflavin corneal cross-linking for infectious keratitis associated with corneal melts. *Cornea* 2008; **27**: 590–594.
- Makdoui K, Mortensen J, Crafoord S. Infectious keratitis treated with corneal crosslinking. *Cornea* 2010; **29**: 1353–1358. Epub 2010/11/26.
- Martins SA, Combs JC, Noguera G *et al*. Antimicrobial efficacy of riboflavin/UVA combination (365 nm) in vitro for bacterial and fungal isolates: a potential new treatment for infectious keratitis. *Investigative Ophthalmology & Visual Science* 2008; **49**: 3402–3408. Epub 2008/04/15.
- Moren H, Malmso M, Mortensen J *et al*. Riboflavin and ultraviolet a collagen crosslinking of the cornea for the treatment of keratitis. *Cornea* 2010; **29**: 102–104. Epub 2009/09/05.
- Schrier A, Greebel G, Attia H *et al*. In vitro antimicrobial efficacy of riboflavin and ultraviolet light on *Staphylococcus aureus*, methicillin-resistant *Staphylococcus aureus*, and *Pseudomonas aeruginosa*. *Journal of refractive surgery* 2009; **25**: S799–S802. Epub 2009/09/24.
- Ollivier FJ, Brooks DE, Kallberg ME *et al*. Evaluation of various compounds to inhibit activity of matrix metalloproteinases in the tear film of horses with ulcerative keratitis. *American Journal of Veterinary Research* 2003; **64**: 1081–1087. Epub 2003/09/19.
- Ollivier FJ, Gilger BC, Barrie KP *et al*. Proteinases of the cornea and precorneal tear film. *Veterinary Ophthalmology* 2007; **10**: 199–206. Epub 2007/06/15.
- Gilger N. Diseases and surgery of the canine cornea and sclera. In: *Veterinary Ophthalmology*. (ed. Gelatt KN) Blackwell Pub, Ames, Iowa, 2007; 643.
- Panda A, Satpathy G, Nayak N *et al*. Demographic pattern, predisposing factors and management of ulcerative keratitis: evaluation of one thousand unilateral cases at a tertiary care centre. *Clinical & Experimental Ophthalmology* 2007; **35**: 44–50. Epub 2007/02/16.
- Thylefors B, Negrel AD, Pararajasegaram R *et al*. Available data on blindness (update 1994). *Ophthalmic epidemiology* 1995; **2**: 5–39. Epub 1995/03/01.
- Thylefors B, Negrel AD, Pararajasegaram R *et al*. Global data on blindness. *Bulletin of the World Health Organization* 1995; **73**: 115–121. Epub 1995/01/01.
- Wong T, Ormonde S, Gamble G *et al*. Severe infective keratitis leading to hospital admission in New Zealand. *The British Journal of Ophthalmology* 2003; **87**: 1103–1108. Epub 2003/08/21.
- Marlar AB, Miller PE, Canton DD *et al*. Canine keratomycosis: a report of eight cases and literature review. *Journal of the American Animal Hospital Association* 1994; **30**: 331–340.
- Massa KL, Murphy CJ, Hartmann FA *et al*. Usefulness of aerobic microbial culture and cytologic evaluation of corneal specimens in the diagnosis of infectious ulcerative keratitis in animals. *Journal of the American Veterinary Medical Association* 1999; **215**: 1671–1674. Epub 2003/10/22.

21. Murphy JM, Lavach JD, Severin GA. Survey of conjunctival flora in dogs with clinical signs of external eye disease. *Journal of the American Veterinary Medical Association* 1978; **172**: 66–68. Epub 1978/01/01.
22. Ledbetter EC, Dubovi EJ, Kim SG *et al.* Experimental primary ocular canine herpesvirus-1 infection in adult dogs. *American Journal of Veterinary Research* 2009; **70**: 513–521. Epub 2009/04/02.
23. Hoover EA, Rohovsky MW, Griesemer RA. Experimental feline viral rhinotracheitis in the germfree cat. *American Journal of Pathology* 1970; **58**: 269–282. Epub 1970/02/01.
24. Pedersen KB, Froholm LO, Bovre K. Fimbriation and colony type of *Moraxella bovis* in relation to conjunctival colonization and development of keratoconjunctivitis in cattle. *Acta Pathologica et Microbiologica Scandinavica. Section B: Microbiology and Immunology* 1972; **80**: 911–918. Epub 1972/01/01.
25. Fini ME, Girard MT. Expression of collagenolytic/gelatinolytic metalloproteinases by normal cornea. *Investigative Ophthalmology & Visual Science* 1990; **31**: 1779–1788. Epub 1990/09/01.
26. Perez VL, Azar DT, Foster CS. Sterile corneal melting and necrotizing scleritis after cataract surgery in patients with rheumatoid arthritis and collagen vascular disease. *Seminars in Ophthalmology* 2002; **4**: 124–130. Epub 2003/05/22.
27. Marcon AS, Rapuano CJ, Tabas JG. Tissue adhesive to treat 2-site corneal melting associated with topical ketorolac use. *Journal of Cataract and Refractive Surgery* 2003; **29**: 393–394. Epub 2003/03/22.
28. Geerling G, Jousen AM, Daniels JT *et al.* Matrix metalloproteinases in sterile corneal melts. *Annals of the New York Academy of Sciences* 1999; **878**: 571–574. Epub 1999/07/23.
29. Varges R, Penna B, Martins G *et al.* Antimicrobial susceptibility of *Staphylococci* isolated from naturally occurring canine external ocular diseases. *Veterinary Ophthalmology* 2009; **12**: 216–220. Epub 2009/07/17.
30. Kern TJ. Ulcerative Keratitis. *Veterinary Clinics of North America* 1990; **20**: 643–666.
31. Spoerl E, Wollensak G, Seiler T. Increased resistance of crosslinked cornea against enzymatic digestion. *Current Eye Research* 2004; **29**: 35–40.
32. Mazzotta C, Balestrazzi A, Traversi C *et al.* Treatment of progressive keratoconus by riboflavin-UVA-induced cross-linking of corneal collagen: ultrastructural analysis by Heidelberg Retinal Tomograph II in vivo confocal microscopy in humans. *Cornea* 2007; **26**: 390–397. Epub 2007/04/26.
33. Dhaliwal JS, Kaufman SC. Corneal collagen cross-linking: a confocal, electron, and light microscopy study of eye bank corneas. *Cornea* 2009; **28**: 62–67. Epub 2008/12/19.
34. Wollensak G, Spoerl E, Wilsch M *et al.* Keratocyte apoptosis after corneal collagen cross-linking using riboflavin/UVA treatment. *Cornea* 2004; **23**: 43–49. Epub 2004/01/01.
35. Spoerl E, Mrochen M, Sliney D *et al.* Safety of UVA-riboflavin cross-linking of the cornea. *Cornea* 2007; **26**: 385–389. Epub 2007/04/26.
36. Kymionis GD, Diakonis VF, Kalyvianaki M *et al.* One-year follow-up of corneal confocal microscopy after corneal cross-linking in patients with post laser in situ keratomileusis ectasia and keratoconus. *American Journal of Ophthalmology* 2009; **147**: 774–778. Epub 2009/02/10.
37. Wollensak G, Spoerl E, Wilsch M *et al.* Endothelial cell damage after riboflavin-ultraviolet-A treatment in the rabbit. *Journal of Cataract and Refractive Surgery* 2003; **29**: 1786–1790. Epub 2003/10/03.
38. Wollensak G, Spoerl E, Reber F *et al.* Corneal endothelial cytotoxicity of riboflavin/UVA treatment in vitro. *Ophthalmic Research* 2003; **35**: 324–328. Epub 2003/12/23.
39. Anwar HM, El-Danasoury AM, Hashem AN. Corneal collagen crosslinking in the treatment of infectious keratitis. *Clinical Ophthalmology* 2011; **5**: 1277–1280. Epub 2011/10/04.
40. Kozobolis V, Labiris G, Gkika M *et al.* UV-A Collagen Cross-Linking Treatment of Bullous Keratopathy Combined With Corneal Ulcer. *Cornea* 2010; **29**: 235–238. Epub 2009/12/22.
41. Muller L, Thiel MA, Kipfer-Kauer AI *et al.* Corneal cross-linking as supplementary treatment option in melting keratitis: a case series. *Klinische Monatsblätter Für Augenheilkunde* 2012; **229**: 411–415. Epub 2012/04/13.
42. Makdoui K, Mortensen J, Sorkhabi O *et al.* UVA-riboflavin photochemical therapy of bacterial keratitis: a pilot study. *Graefes Archive for Clinical and Experimental Ophthalmology* 2012; **250**: 95–102. Epub 2011/08/30.
43. Raiskup-Wolf F, Hoyer A, Spoerl E *et al.* Collagen crosslinking with riboflavin and ultraviolet-A light in keratoconus: long-term results. *Journal of Cataract and Refractive Surgery* 2008; **34**: 796–801.
44. Wollensak G, Spoerl E, Seiler T. Stress-strain measurements of human and porcine corneas after riboflavin-ultraviolet-A-induced cross-linking. *Journal of Cataract and Refractive Surgery* 2003; **29**: 1780–1785. Epub 2003/10/03.
45. Ito K, Inoue S, Yamamoto K *et al.* 8-Hydroxydeoxyguanosine formation at the 5' site of 5'-GG-3' sequences in double-stranded DNA by UV radiation with riboflavin. *Journal of Biological Chemistry* 1993; **268**: 13221–13227. Epub 1993/06/25.
46. Tsugita A, Okada Y, Uehara K. Photosensitized inactivation of ribonucleic acids in the presence of riboflavin. *Biochimica et Biophysica Acta* 1965; **103**: 360–363. Epub 1965/06/08.
47. Cardo LJ, Rentas FJ, Ketchum L *et al.* Pathogen inactivation of *Leishmania donovani* infantum in plasma and platelet concentrates using riboflavin and ultraviolet light. *Vox Sanguinis* 2006; **90**: 85–91. Epub 2006/01/25.
48. Cardo LJ, Salata J, Mendez J *et al.* Pathogen inactivation of *Trypanosoma cruzi* in plasma and platelet concentrates using riboflavin and ultraviolet light. *Transfusion and Apheresis Science* 2007; **37**: 131–137. Epub 2007/10/24.
49. Corbin F 3rd. Pathogen inactivation of blood components: current status and introduction of an approach using riboflavin as a photosensitizer. *International Journal of Hematology* 2002; **76** (Suppl 2): 253–257. Epub 2002/11/15.
50. Kumar V, Lockerbie O, Keil SD *et al.* Riboflavin and UV-light based pathogen reduction: extent and consequence of DNA damage at the molecular level. *Photochemistry and Photobiology* 2004; **80**: 15–21. Epub 2004/09/02.
51. Reddy HL, Dayan AD, Cavagnaro J *et al.* Toxicity testing of a novel riboflavin-based technology for pathogen reduction and white blood cell inactivation. *Transfusion Medicine Reviews* 2008; **22**: 133–153. Epub 2008/03/21.
52. Ruane PH, Edrich R, Gamp D *et al.* Photochemical inactivation of selected viruses and bacteria in platelet concentrates using riboflavin and light. *Transfusion* 2004; **44**: 877–885. Epub 2004/05/26.
53. Galperin G, Berra M, Tau J *et al.* Treatment of fungal keratitis from *Fusarium* infection by corneal cross-linking. *Cornea* 2012; **31**: 176–180. Epub 2011/11/15.
54. Wollensak G, Wilsch M, Spoerl E *et al.* Collagen fiber diameter in the rabbit cornea after collagen crosslinking by riboflavin/UVA. *Cornea* 2004; **23**: 503–507. Epub 2004/06/29.
55. Cullen CL, Wadowska DW, Singh A *et al.* Ultrastructural findings in feline corneal sequestra. *Veterinary Ophthalmology* 2005; **8**: 295–303. Epub 2005/09/24.

56. Kaswan RL, Salisbury MA, Ward DA. Spontaneous canine keratoconjunctivitis sicca. A useful model for human keratoconjunctivitis sicca: treatment with cyclosporine eye drops. *Archives of Ophthalmology* 1989; **107**: 1210–1216.
57. Yi NY, Park SA, Jeong MB *et al.* Medial canthoplasty for epiphora in dogs: a retrospective study of 23 cases. *Journal of the American Animal Hospital Association* 2006; **42**: 435–439. Epub 2006/11/08.
58. Gwin RM, Lerner I, Warren JK *et al.* Decrease in canine corneal endothelial cell density and increase in corneal thickness as functions of age. *Investigative Ophthalmology & Visual Science* 1982; **22**: 267–271.
59. Gokhale NS. Corneal endothelial damage after collagen cross-linking treatment. *Cornea* 2011; **30**: 1495–1498. Epub 2011/10/18.
60. Kolli S, Aslanides IM. Safety and efficacy of collagen crosslinking for the treatment of keratoconus. *Expert Opinion on Drug Safety* 2010; **9**: 949–957. Epub 2010/06/08.
61. Hakanson N, Merideth RE. Conjunctival pedicle grafting in the treatment of corneal ulcers in the dog and cat. *Journal of the American Animal Hospital Association* 1987; **23**: 641–648.
62. Hakanson N, Merideth RE. Further comments on conjunctival pedicle grafting in the treatment of corneal ulcers in the dog and cat. *Journal of the American Animal Hospital Association* 1988; **24**: 602–605.
63. Asri D, Touboul D, Fournie P *et al.* Corneal collagen crosslinking in progressive keratoconus: multicenter results from the French National Reference Center for Keratoconus. *Journal of Cataract and Refractive Surgery* 2011; **37**: 2137–2143. Epub 2011/11/24.
64. Greenstein SA, Fry KL, Hersh PS. In vivo biomechanical changes after corneal collagen cross-linking for keratoconus and corneal ectasia: 1-year analysis of a randomized, controlled, clinical trial. *Cornea* 2012; **31**: 21–25. Epub 2011/10/14.
65. Wittig-Silva C, Whiting M, Lamoureux E *et al.* A randomized controlled trial of corneal collagen cross-linking in progressive keratoconus: preliminary results. *Journal of refractive surgery* 2008; **24**: S720–S725. Epub 2008/09/25.
66. Caporossi A, Mazzotta C, Baiocchi S *et al.* Long-term results of riboflavin ultraviolet a corneal collagen cross-linking for keratoconus in Italy: the Siena eye cross study. *American Journal of Ophthalmology* 2010; **149**: 585–593. Epub 2010/02/09.
67. Hersh PS, Greenstein SA, Fry KL. Corneal collagen crosslinking for keratoconus and corneal ectasia: One-year results. *Journal of Cataract and Refractive Surgery* 2011; **37**: 149–160. Epub 2010/12/25.