

Transitory Topographical Variations in Keratoconus During Pregnancy

Florence Hoogewoud, MD; Zisis Gatziofufas, MD, PhD;
Farhad Hafezi, MD, PhD

ABSTRACT

PURPOSE: To highlight two cases of keratoconus with significant variations of corneal curvature during pregnancy that reversed several months after delivery.

METHODS: Case reports and literature review.

RESULTS: Two women experienced a significant decrease of corrected distance visual acuity during pregnancy. Evaluation of corneal topography by Scheimpflug imaging revealed transitory variations of the keratometric values in both patients during the gestational period. These topographical alterations were evident not only during pregnancy, but also in the postpartum period, with stabilization of corneal topography several months after delivery.

CONCLUSIONS: These clinical cases indicate that hormonal changes occurring regularly during gestation may have a severe impact on the progression of keratoconus. However, these changes are transient and fully reversible. Therefore, physicians should be reluctant to perform cross-linking during or directly after pregnancy and should wait until the corneal curvature has been stabilized. [J Refract Surg 2013;29:144-146.]

Keratoconus is a multifactorial corneal disease leading to ectasia of the corneal tissue and severely affecting visual acuity. Several mechanisms may contribute to the pathophysiology of keratoconus: degradation of corneal stroma, oxidative damage, mechanical corneal injury due to eye rubbing, and immunological and genetic factors.¹

Currently, cutting edge research is focused on the impact of hormonal influences on corneal biomechanical properties. It is well established that thyroid hormones play a crucial role in corneal dehydration and transparency during embryonic development.² Moreover, female sex hormones affect distinctly ocular physiology

and pathophysiology, particularly during pregnancy.³ There is evidence that those influences may induce significant alterations of the corneal biostability in vitro and exacerbate underlying corneal ectasia.⁴

We highlight two cases of keratoconus with significant variations of corneal curvature during pregnancy that reversed after delivery, suggesting that hormonal changes occurring regularly during gestation may have a significant impact on the progression of the disease.

CASE REPORTS

CASE 1

A 32-year-old woman in good health and without ophthalmological history was referred for ophthalmic evaluation by an optician because of progressive loss of corrected distance visual acuity (CDVA) and was diagnosed as having bilateral keratoconus. During 20 weeks of gestation of her first pregnancy, CDVA worsened bilaterally. A maximal keratometry value (Kmax) increase of 3.60 diopters (D) in the right eye and 1.00 D in the left eye was observed by Scheimpflug imaging (Allegro Oculyzer, Wavelight, Erlanger, Germany). Keratometric findings remained stable in the right eye and improved slightly in the left eye (1.00 D decrease) at 29 weeks of gestation. Six months postpartum, keratometric values remained stable in the right eye, whereas the left eye showed a decrease of 1.20 D. One year later at the next follow-up examination, with the patient at 16 weeks of gestation in her second pregnancy, keratometric values were unchanged in the right eye but the left eye showed an increase of 1.50 D. At 34 weeks of gestation, keratometric values in the right eye deteriorated further by 2.40 D, whereas the left eye remained stable. The variations of the topographic findings are depicted in **Figure 1**. In the year following the second pregnancy, CDVA and corneal topography remained stable.

CASE 2

A 26-year-old woman in good health and with no ophthalmological history was referred 1 month prior to her first pregnancy because of progressive loss of CDVA with increasing astigmatism over 5 years. Bilateral keratoconus was diagnosed with the aid of Scheimpflug imaging (Pentacam HR; Oculus Optikgeräte GmbH, Wetzlar, Germany). At 29 weeks of gestation, Kmax showed a decrease of 4.50 D in the right eye and 1.00 D in the left eye. One month later, at 33 weeks of gestation, the improvement seen previously had partially reversed with an increase of Kmax by 1.30 D in the right eye and 0.50 D in the left eye. At 3 months postpartum, Kmax returned to pregestational levels. The changes in corneal topography are shown in **Figure 2**.

From the Department of Ophthalmology, Geneva University Hospitals, Geneva, Switzerland (FHoogewoud, ZG, FHafezi); and Doheny Eye Institute, Department of Ophthalmology, Keck School of Medicine, University of Southern California, Los Angeles, California (FHafezi).

Submitted: October 3, 2012; Accepted: November 20, 2012

The authors have no financial or proprietary interest in the materials presented herein.

Correspondence: Zisis Gatziofufas, MD, PhD, Geneva University Hospitals, Rue Alcide-Jentzer 22, 1211 Geneva, Switzerland. E-mail: zisisg@hotmail.com

doi:10.3928/1081597X-20130117-11

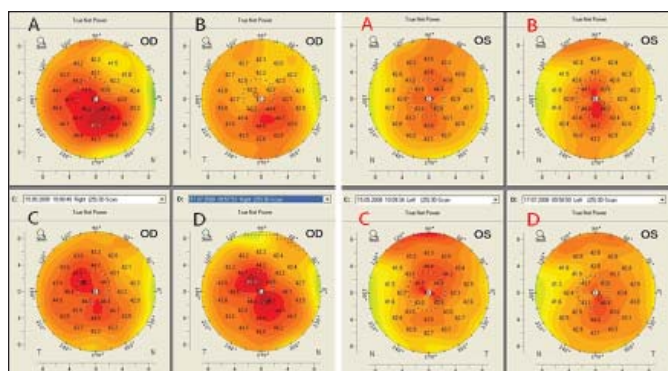


Figure 1. Corneal topographical variations of case 1 as evaluated by Allegro Oculyzer imaging (Wavelight, Erlanger, Germany). Corneal topography (A) before the first pregnancy, (B) at 4 weeks of gestation, (C) at 20 weeks of gestation, and (D) at 29 weeks of gestation. Numeration in black corresponds to the right eye and in red to the left eye.

DISCUSSION

Our two cases of keratoconus demonstrated transitory fluctuations of the corneal topographic data during pregnancy, suggesting that gestational hormonal changes may affect the progression of the disease. In the first case, bilateral topographical deterioration was observed during the first trimester of the first pregnancy. In the second case, improvement of the keratometric values was observed in both eyes at 29 weeks of gestation, when the progesterone level is still superior to the estrogen level. Similar to the first case, this improvement reversed by the end of the pregnancy.

The physiological effects of estrogen, progesterone, and pregnancy on the cornea have not been investigated extensively. Refractive changes during pregnancy are not uncommon, but relevant evidence is still limited. In a study including 83 pregnant women, 12 patients manifested diminished CDVA and had a myopic shift of approximately 0.90 D during pregnancy, which was restored after the lactation period.⁵ Park et al.⁶ reported an increased rate of contact lens intolerance during pregnancy, due to an increase of corneal curvature. Corneal sensitivity has also been described to decrease during the last trimester of pregnancy.⁷ An increase in corneal thickness during pregnancy,⁸ at the end of the menstrual cycle, and at the time of ovulation has also been documented.⁹ The increased corneal thickness during ovulation is associated with decreased corneal hysteresis and decreased corneal resistant factor.⁹ This decreased mechanical resistance occurs during the highest peak of estrogen in the menstruation cycle when the progesterone level is still low, but it has not been observed at the end of the cycle during the second lower peak of estrogen. Whether progesterone has a protective effect on corneal softening is unknown. However, progesterone prevents relaxin and beta-estradiol mediated matrix degradation of

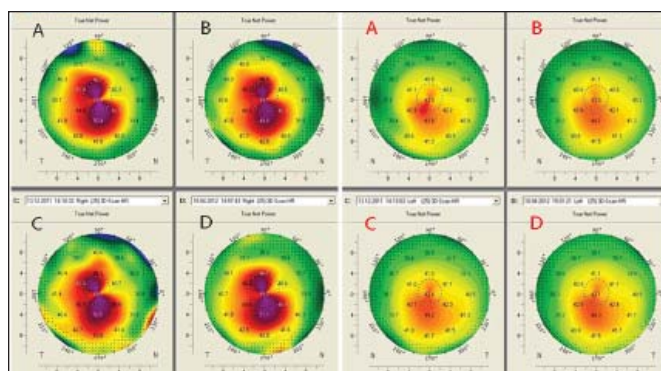


Figure 2. Corneal topographical variations of case 2 as evaluated by Pentacam HR (Oculus Optikgeräte GmbH, Wetzlar, Germany). Corneal topography (A) before pregnancy, (B) at 29 weeks of gestation, (C) at 33 weeks of gestation, and (D) in the postpartum period. Numeration in black corresponds to the right eye and in red to the left eye.

fibrocartilaginous tissue *in vivo*.¹⁰ Corneal biomechanics during pregnancy have not yet been investigated in a study-based manner. Nonetheless, a case of keratoconus progression with development of acute corneal hydrops induced by thyrotoxicosis has been reported during pregnancy¹¹ and two cases of pregnancy-associated keratectasia have been described.^{12,13}

The ocular effects of relaxin, which is responsible for softening of the pubis during pregnancy, are unknown. During pregnancy, relaxin levels reach a peak at 14 weeks of gestation and remain high during the last half of pregnancy.¹⁴ Relaxin-induced degradation of knee cartilage has been demonstrated *in vivo*, due to up-regulation and activation of matrix metalloproteinases (MMPs).¹⁵ The implication of MMPs in the pathophysiology of keratoconus is well established.¹⁶ The levels of MMPs (especially MMP-1, MMP-2, and MMP-9) in corneal stroma are significantly increased in keratoconus, whereas the level of tissue inhibition of MMP-1 is decreased in keratoconic corneas.¹⁶ In addition, keratoconic corneas demonstrate elevated levels of cathepsins V/L2, -B, and -G, which also play an important role in the matrix degradation occurring in corneal stroma in keratoconus.¹⁶ It is interesting that relaxin concentration shows a preovulatory peak, corresponding to the peak of corneal softening during the menstrual cycle.

On the other hand, MMPs play a crucial role in the process of embryo implantation, regulating the trophoblastic invasion during pregnancy.¹⁷ Human chorionic gonadotropin is produced in the first semester of the pregnancy, inducing an upregulation of MMP secretion by the trophoblast (especially MMP-9).¹⁷ The ovarian extracellular matrix remodeling mediated by MMP is required for the establishment of pregnancy and the pattern of MMP expression during the first trimester of pregnancy resembles that of the corneal extracellular matrix in keratoconus.¹⁷

Our two cases of keratoconus demonstrated variable fluctuations of the corneal topographic data during pregnancy, suggesting that gestational hormonal changes may affect the progression of the disease. These clinical observations support the clinical hypothesis that progesterone may exert a preventive effect on the progression of keratoconus during the second half of the pregnancy and estrogen alone or combined with other hormones such as relaxin may induce a diminution of the corneal stiffness with subsequent exacerbation of the disease in the first half and at the end of the pregnancy. However, the complex nature of the underlying pathophysiology is still unknown. These topographical alterations appear to be transitory and reversible, because corneal topographic values in both cases reached pregestational levels several months after birth. Therefore, we recommend that physicians be reluctant to perform cross-linking during or directly after pregnancy and wait until the corneal curvature has been stabilized, which occurs several months after delivery.

Further studies are required to delineate the role of hormonal changes during pregnancy in ocular physiology and thereby increase our understanding of the complex interaction between hormonal status and corneal physiology in normal and keratoconic cornea.

AUTHOR CONTRIBUTIONS

Study concept and design (FHoogewoud); data collection (FHoogewoud); analysis and interpretation of data (ZG, FHafezi); drafting of the manuscript (FHoogewoud); critical revision of the manuscript (ZG, FHafezi); supervision (FHafezi)

REFERENCES

1. Rabinowitz YS. Keratoconus. *Surv Ophthalmol*. 1998;42(4):297-319.
2. Coulombre AJ, Coulombre JL. Corneal development 3: the role of the thyroid in dehydration and the development of transparency. *Exp Eye Res*. 1964;3:105-114.
3. Sunness JS. The pregnant woman's eye. *Surv Ophthalmol*. 1988;32(4):219-238.
4. Spoerl E, Zubaty V, Raiskup-Wolf F, Pillunat LE. Oestrogen-induced changes in biomechanics in the cornea as a possible reason for keratectasia. *Br J Ophthalmol*. 2007;91(11):1547-1550.
5. Pizzarello LD. Refractive changes in pregnancy. *Graefes Arch Clin Exp Ophthalmol*. 2003;241(6):484-488.
6. Park SB, Lindahl KJ, Temnycky GO, Aquavella JV. The effect of pregnancy on corneal curvature. *CLAO J*. 1992;18(4):256-259.
7. Millodot M. The influence of pregnancy on the sensitivity of the cornea. *Br J Ophthalmol*. 1977;61(10):646-649.
8. Weinreb RN, Lu A, Beeson C. Maternal corneal thickness during pregnancy. *Am J Ophthalmol*. 1988;105(3):258-260.
9. Goldich Y, Barkana Y, Pras E, et al. Variations in corneal biomechanical parameters and central corneal thickness during the menstrual cycle. *J Cataract Refract Surg*. 2011;37(8):1505-1511.
10. Hashem G, Zhang Q, Hayami T, Chen J, Wang W, Kapila S. Relaxin and beta-estradiol modulate targeted matrix degradation in specific synovial joint fibrocartilages: progesterone prevents matrix loss. *Arthritis Res Ther*. 2006;8(4):R98.
11. Gatziofas Z, Thanos S. Acute keratoconus induced by hypothyroxinemia during pregnancy. *J Endocrinol Invest*. 2008;31(3):262-266.
12. Padmanabhan P, Radhakrishnan A, Natarajan R. Pregnancy-triggered iatrogenic (post-laser in situ keratomileusis) corneal ectasia-a case report. *Cornea*. 2010;29(5):569-572.
13. Hafezi F, Iseli HP. Pregnancy-related exacerbation of iatrogenic keratectasia despite corneal collagen crosslinking. *J Cataract Refract Surg*. 2008;34(7):1219-1221.
14. Conrad KP. Emerging role of relaxin in the maternal adaptations to normal pregnancy: implications for preeclampsia. *Semin Nephrol*. 2011;31(1):15-32.
15. Kapila S, Wang W, Uston K. Matrix metalloproteinase induction by relaxin causes cartilage matrix degradation in target synovial joints. *Ann N Y Acad Sci*. 2009;1160:322-328.
16. Balasubramanian SA, Pye DC, Willcox MD. Are proteases the reason for keratoconus? *Curr Eye Res*. 2010;35(3):185-191.
17. Curry TE Jr, Smith MF. Impact of extracellular matrix remodeling on ovulation and the folliculo-luteal transition. *Semin Reprod Med*. 2006;24(4):228-241.