

## CASE REPORT

# Treatment of bullous keratopathy with corneal collagen cross-linking in two dogs

Simon A. Pot,\* Nicolin S. Gallhöfer,\* Ladina Walser-Reinhardt,† Farhad Hafezi‡ and Bernhard M. Spiess\*

\*Equine Department, Vetsuisse Faculty, University of Zurich, Winterthurerstrasse 260, CH-8057 Zurich, Switzerland; †Vetaugenblick, Tierklinik Masans, Masanserstrasse 143, CH-7000 Chur, Switzerland; and ‡Department of Ophthalmology, Geneva University Hospitals, Rue Alcide-Jentzer 22, CH-1211 Geneva 14, Switzerland

Address communications to:

S. A. Pot

Tel.: +41 44 635 9030

Fax: +41 44 635 8940

e-mail: spot@vetclinics.uzh.ch

## Abstract

**Objective** Corneal collagen cross-linking with riboflavin and UV-A (CXL) decreases corneal oedema and increases visual acuity in human patients with bullous keratopathy. Presumed mechanisms are an increase in collagen packing density and a reduction in stromal swelling pressure. We present two cases in which CXL was used to treat bullous keratopathy in dogs.

**Procedures** Four eyes of two dogs with painful bullous keratopathy-induced corneal erosions that were resistant to prior therapy were treated with CXL. Both corneas of the second patient were dehydrated to  $\pm 400 \mu\text{m}$  corneal thickness using topical 70% glycerol solution immediately prior to CXL. Follow-up included slit-lamp examination, fluorescein staining and photographic documentation in both cases and high-resolution ultrasound examination in the second patient.

**Results** All four eyes were comfortable and fluorescein negative at 1-week post-CXL and remained so for the rest of the follow-up period (17.5 months for case 1 and 6 months for case 2). The owner of the first patient reported a less oedematous cornea and improvement in vision that lasted for 6 months. Despite a reported lack of improvement in vision in the second patient, corneal thickness initially decreased, but was back at baseline thickness at the 4-month recheck.

**Conclusions** Similar to humans, CXL might become a useful treatment option for bullous keratopathy-induced therapy-resistant corneal erosions in dogs. Patient comfort was greatly improved, but corneal thickness decrease was not as long-lasting as reported for humans. The presently used protocols might need modification to fit the dog cornea.

**Key Words:** bullous keratopathy, cornea, corneal collagen cross-linking, dog, endothelial decompensation, oedema

## INTRODUCTION

Corneal collagen cross-linking (CXL) is based on the exposure of the photosensitizer riboflavin (Vitamin B2) to UV-A light with a wavelength at the riboflavin absorption peak of 370 nm. This results in a free oxygen radical-driven photopolymerization process introducing additional covalent cross-links within collagen fibres and in the proteoglycan–glycosaminoglycan ground substance of the corneal stroma up to a depth of 300  $\mu\text{m}$ .<sup>1,2</sup> The result is

an increase in the biomechanical and biochemical stability of the cornea, an increase in collagen packing density and a reduction in the swelling tendency of the glycosaminoglycan-rich hydrophilic ground substance of the cornea. Reactive oxygen species (ROS)-induced damage to cells and reduction in microorganisms in the irradiated area has been described as well.<sup>3–8</sup>

After CXL was introduced for the treatment of progressive keratoconus in humans,<sup>9</sup> new indications for the clinical use of CXL emerged rapidly, including the treatment of

melting keratitis, Fuchs' dystrophy and bullous keratopathy.<sup>10,11</sup> Melting keratitis and bullous keratopathy are two interesting indications for the use of CXL in veterinary medicine, as these diseases are potentially blinding and can be difficult to control both medically and surgically.<sup>12</sup> The effective use of CXL for the treatment of melting keratitis in dogs, cats and horses was recently reported.<sup>13–16</sup>

Various congenital and acquired diseases including breed-related endothelial dystrophy, iris-to-cornea persistent pupillary membranes, trauma (both surgical and non-surgical), anterior uveitis/endotheliitis, glaucoma, toxic damage to the endothelium, age-related endothelial degeneration and melting keratitis can cause functional decompensation of the corneal endothelium and result in bullous keratopathy.<sup>12</sup> Pain and discomfort are caused by the recurrent or nonhealing corneal erosions that occur with bullous keratopathy. The dense corneal oedema results in significant loss of vision and even blindness in severe cases. Topical application of hypertonic solutions and ointments can decrease the extent of epithelial oedema and bullae formation, but typically does not significantly decrease the extent of the stromal oedema and opacification. The frequent necessary application and local irritation can limit the usefulness of topical hypertonic saline treatment.<sup>12</sup> More invasive treatments including thermokeratoplasty<sup>17</sup> and 360° conjunctival flap (Gunderson flap) placement can be used successfully to treat the epithelial defects, but these treatments further decrease corneal transparency.<sup>12</sup> Partial coverage of the corneal surface with a thin conjunctival flap can function as a drainage sink for the oedematous fluid in the stroma. This has been observed to subjectively increase corneal transparency (P. Bedford, personal communication; I. Allgoewer, personal communication); however, the duration of this effect is unknown.

Corneal collagen cross-linking with riboflavin and UV-A (CXL) decreases corneal oedema and increases visual acuity in human patients with bullous keratopathy.<sup>11</sup> Presumed mechanisms are an increase in collagen packing density and a reduction in the swelling tendency of the glycosaminoglycan-rich hydrophilic ground substance of the cornea.<sup>3</sup> The objective of this case report was to evaluate the effectiveness of CXL for the treatment of bullous keratopathy in dogs.

## METHODS

Four eyes of two dogs with a two-month history of persistent corneal erosions as a result of bullous keratopathy were treated with CXL at the veterinary clinical teaching hospital of the Veterinary (Vetsuisse) Faculty of the University of Zurich, Switzerland.

### *Pretreatment and post-treatment examinations*

Both patients underwent slit-lamp examination (SL 15; Kowa Optimed Europe Ltd., Sandhurst, UK), fluorescein

staining (Fluorescein Sodium; Acrivet-Veterinary Division, Hennigsdorf, Germany), Schirmer tear testing (Schirmer Tear Test; Intervet/Schering-Plough Animal Health, Roseland, NJ, USA), tonometry (TonoVet; ICare, Vantaa, Finland), indirect ophthalmoscopy (Omega 500, HEINE Optotechnik, Herrsching, Germany; 2.2 PanRetinal and 28D lenses, Volk Optical Inc., Mentor, OH, USA) and photographic documentation (Nikon D90 camera and Nikon AF Micro Nikkor 60 mm lens; Nikon AG, Egg, Switzerland) at the initial visit. Slit-lamp examination, fluorescein staining and photographic documentation were performed during all follow-up visits. Corneal thickness measurements were performed only on patient 2 during the baseline examination, during the CXL procedure and at each recheck appointment. The corneal thickness measurements before and after CXL and at the first two timepoints during the CXL procedure were obtained via high-resolution ultrasound (40 MHz probe, Eyecubed I-3 System, version 4; Ellex, Innovative Imaging, Sacramento, CA, USA). Corneal thickness was measured from each of the B-scan images using the ultrasound unit's internal callipers. The measurements at the second through eighth timepoint during the CXL procedure were taken with an ultrasound pachymeter (PachPen handheld ultrasound pachymeter; Accutome, Inc., Malvern, PA, USA). The second measurement during the CXL procedure was taken with both modalities with <40 µm difference between measurements. All pachymetry measurements were averaged (2–4 measurements per timepoint). Total follow-up was 17.5 months for case 1 and 6 months for case 2.

### *Patients*

Patient 1, a 13-year-old male neutered Shepherd mix, had been diagnosed with anterior uveitis in both eyes (OU) by the referring veterinarian 2 months prior to referral. A *Rickettsia coronii* infection was the presumed aetiology and treatment with systemic doxycycline (Supracyclin, Grunenthal, 10 mg/kg orally twice daily for 3 weeks) and topical prednisolone acetate 1% (Pred Forte; Allergan, Inc., Irvine, CA, USA) and diclofenac 0.1% (Voltaren, Novartis International AG, Basel, Switzerland) was started at this time. Complete ophthalmic examination at the veterinary clinical teaching hospital of the Veterinary (Vetsuisse) Faculty of the University of Zurich, Switzerland, revealed diffuse, noncystic corneal oedema, central epithelial erosions, mild inferotemporal corneal neovascularization and blepharospasm. Menace responses, dazzle and pupillary light reflexes were present OU and no signs of an active uveitis were observed. An intraocular pressure (IOP) of 7 mmHg was measured in the left eye (OS) and 8 mmHg in the right eye (OD). Schirmer tear test measurements were within normal limits at all measured timepoints. A fundic examination was severely limited by the lack of corneal transparency and patient cooperation. Oral doxycycline was continued and topical neomycin/poly-myxin/bacitracin ointment (Ophthalmivet, Vetoquinol)

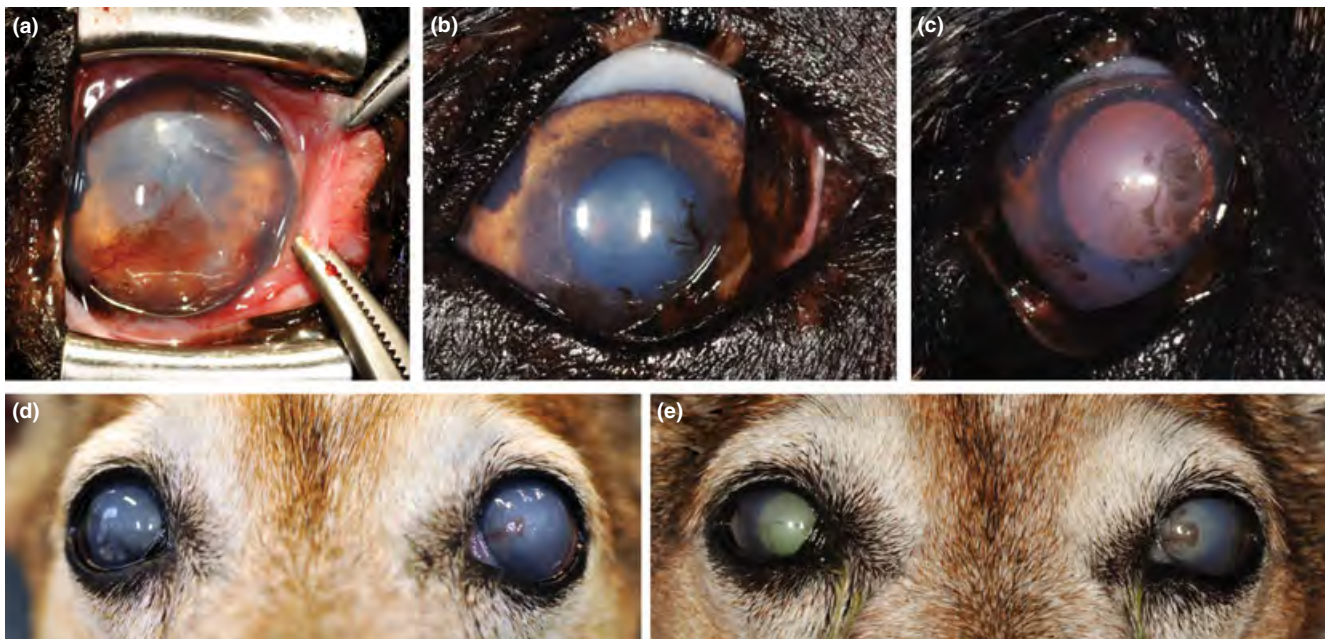
was started three times daily OU. During the 2 months following this visit, the patient was repeatedly seen by an ECVO Diplomate in private practice (LWR), who confirmed the diagnosis of endothelial decompensation and absence of active uveitis. During this period, the patient was treated twice with cotton tip applicator and diamond burr (Algerbrush II; The Alger Company, Inc., Lago Vista, TX, USA) debridement and bandage contact lens placement (Acrivet Pat D2, Acrivet). Following these treatments, the patient was comfortable with the contact lenses in place, but discomfort returned due to the presence of persistent corneal erosions as soon as the contact lenses were removed. Treatment with topical broad spectrum antibiotics was continued throughout the treatment period.

The patient was again referred to the Veterinary (Vetsuisse) Faculty of the University of Zurich, Switzerland, for CXL treatment OU. Microcystic corneal oedema, corneal epithelial bullae and erosions, mild to moderate inferotemporal corneal neovascularization and pigmentation and multifocal depigmentation of the nictitating membrane were observed OU (Fig. 1a). CXL was performed OU under general anaesthesia as previously described.<sup>13</sup> A bandage contact lens (Acrivet Pat D2, Acrivet) was placed OU immediately after CXL. Treatment was started with topical ofloxacin (Floxal, Bausch & Lomb Swiss AG, Zug,

Switzerland) eye drops three times daily OU and oral tramadol (Tramadol Mepha; Mepha Pharma AG, Basel, Switzerland) at 3–5 mg/kg up to three times daily as needed for pain. The patient was discharged from the clinic on the day of the procedure. Via telephone follow-up the next day, the owner reported conjunctival redness and intermittent blepharospasm, which resolved during exercise.

Both eyes were comfortable and both contact lenses were removed (LWR) 1 week after the CXL procedure. The corneas were both fluorescein negative.

Two weeks after the CXL procedure, both corneas were comfortable, subjectively less oedematous and fluorescein negative with a smooth epithelial surface. The corneal neovascularization and pigmentation and the depigmentation of the nictitating membrane were unchanged and interpreted as being consistent with pre-existent chronic superficial keratitis. Topical treatment was started with cyclosporine 0.2% (Optimmune, MSD Animal Health GmbH, Luzern, Switzerland) three times daily and neomycin/polymyxin/dexamethasone 0.1% (Maxitrol, Alcon, Fort Worth, TX, USA) four times daily OU. These medications were to be tapered to twice daily OU over 8 weeks. At recheck, 2 months later, both corneas remained comfortable and fluorescein negative with a smooth epithelial surface (Fig. 1b). The corneal and nictitating membrane pigmentation were unchanged and the



**Figure 1.** Clinical effect of Corneal collagen cross-linking (CXL) on bullous keratopathy (two patients). Bullous keratopathy as a result of endothelial decompensation was diagnosed in both patients. The appearance OD of case 1 immediately prior to CXL (a). The appearance OS was identical to OD. Note the dense microcystic corneal oedema and epithelial erosion. Fine pigmentation accompanied the neovascularization advancing towards the centre of the cornea (a). The appearance OD 2 (b) and 15 (c) months post-CXL. Both eyes were comfortable with a smooth, fluorescein-negative corneal surface and subjectively less intense corneal oedema. Minimal progression of the pigmentation was present. The appearance of case 2 immediately prior to CXL (d). Note the dense microcystic corneal oedema OU and the irregularity of the corneal surface (OS > OD). A central epithelial erosion was present OU. Radially oriented areas of pigmentation OD and neovascularization OS were present. One week post-CXL, both eyes were comfortable with a smooth, fluorescein-negative corneal surface and less intense corneal oedema (e).



corneal neovascularization had completely regressed OU. Treatment with cyclosporine 0.2% was continued twice daily and neomycin/polymyxin/dexamethasone 0.1% was tapered and discontinued over a 3 month period of time. The owner reported an improvement in visual performance at the 3- and 5-month postprocedure rechecks. At 6.5 months after the CXL procedure, the owner reported decreased corneal transparency and deterioration of visual performance, which were both difficult to confirm clinically. Topical treatment with 5% sodium chloride ointment (Muro 128, Bausch & Lomb) 3–4 times daily OU was added to the cyclosporine treatment. During the rest of the follow-up period up to a recheck at 17.5 months after the CXL procedure, no further changes were observed (Fig. 1c). Due to mild local irritation, application of the 5% sodium chloride ointment was tapered to twice daily OU.

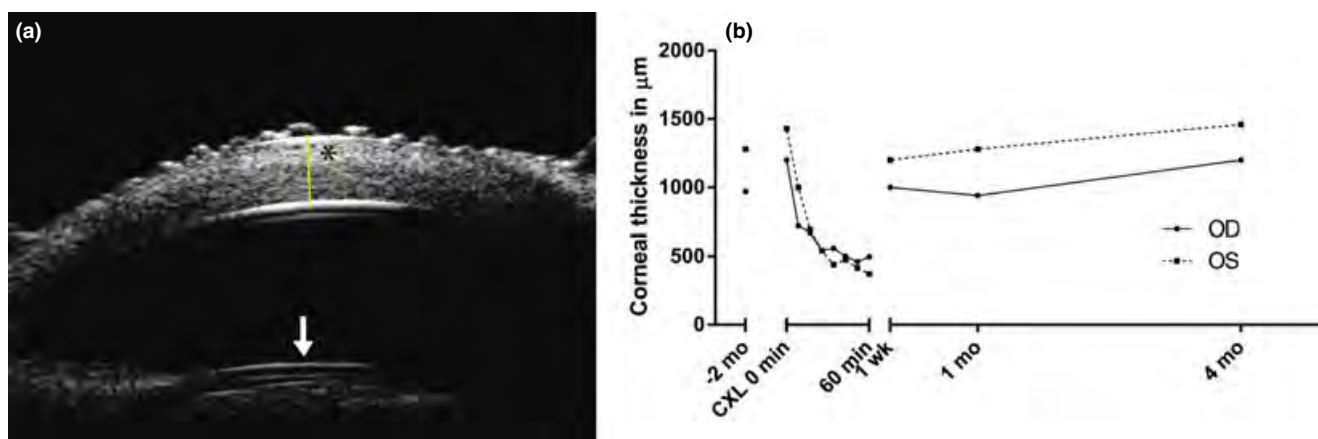
Patient 2, a 14-year-old female castrated Jack Russell Terrier, presented with dense corneal oedema OS and mild to moderate corneal oedema OD. The corneal surface was irregular OU with faint multifocal fluorescein staining OS and a small epithelial erosion OD. Schirmer tear test measurements were within normal limits at all measured timepoints. Corneal thickness was 0.97 mm OD and 1.28 mm OS as measured by high-resolution ultrasound. A complete examination of the anterior chamber was not possible due to the loss of corneal transparency. The iris seemed slightly hyperpigmented. However, no signs of an active uveitis were observed. The patient was diagnosed with corneal endothelial decompensation, which was presumed to be age-related or uveitis-induced based on the iris hyperpigmentation and low IOPs of 3 mmHg OS and 4 mmHg OD that were measured. Topical treatment was started with 5%

sodium chloride ointment four times daily OU. Topical anti-inflammatory treatment was postponed due to the observed corneal surface abnormalities and a follow-up examination was recommended 2 weeks later.

The patient then presented 2 months later with a history of intermittent blepharospasm since the previous visit. No change was observed with the use of 5% sodium chloride ointment, and the episodes of blepharospasm were increase in length and frequency. Ophthalmic examination revealed dense microcystic corneal oedema, irregularity of the corneal surface, central epithelial erosions OU, radially oriented areas of pigmentation OD and neovascularization OS (Fig. 1d). Corneal thickness had increased to 1.2 mm OD and 1.43 mm OS.

Corneal collagen cross-linking was performed OU under general anaesthesia as previously described.<sup>13</sup> Both corneas of the second patient were dehydrated to a corneal thickness of approximately 400  $\mu$ m using topical 70% glycerol solution immediately prior to CXL according to a previously published protocol.<sup>18</sup> This was carried out to increase the proportion of total stromal thickness reached by CXL, which has a penetration limit of  $\pm 300 \mu$ m.<sup>1</sup> Treatment with 5% sodium chloride ointment three times daily was continued and topical neomycin/polymyxin/bacitracin ointment four times daily OU, oral tramadol 3–5 mg/kg up to three times daily as needed and robenacoxib (Onsior, Novartis) 1 mg/kg once daily with food for 3 days were started. Contact lenses were not placed and the patient was discharged from the clinic on the day of the procedure.

One week after the CXL procedure, both eyes were comfortable and fluorescein negative with a dense microcystic corneal oedema and smooth corneal surface



**Figure 2.** Corneal pachymetry data at various timepoints before, during and after Corneal collagen cross-linking (CXL) (patient 2). High-resolution ultrasound (HRUS) image of the central cornea and anterior lens capsule (white arrow) OS of case 2 taken 1 week after CXL (a). A demarcation line was visible between the anterior third and posterior two-thirds of the corneal stroma. The anterior stroma (asterisk) was hyperechogenic compared to the posterior stroma. Digital callipers were used for corneal thickness measurements (yellow line). Corneal thickness of case 2 in  $\mu$ m plotted over time (b). An increase in corneal thickness between the first presentation and the presentation immediately prior to CXL had been observed. The decrease in corneal thickness measured during the CXL procedure was caused by the riboflavin–dextran 20% (decrease between first and second measurement) and glycerol 70% solutions (residual decrease). Four months after CXL, the corneal thickness had returned to the values measured immediately prior to CXL.

(Fig. 1e). According to the owner, there was no improvement in vision. Corneal thickness was 1.06 mm OD and 1.2 mm OS. A demarcation line was visible on ultrasound between the anterior third and posterior two-thirds of the stroma (Fig. 2a). Only topical treatment with 5% sodium chloride ointment three times daily was continued. Apart from mild progression of pigmentation OD and neovascularization OS, the clinical situation at 1 month after the CXL procedure was identical to the corneal appearance 1 week postprocedure. Corneal thickness was 0.94 mm OD and 1.28 mm OS. Topical treatment with 5% sodium chloride ointment three times daily OU was continued and topical treatment with cyclosporine 0.2% and ketorolac 0.5% (Acular, Allergan) twice daily OU was initiated. During the remainder of the follow-up period at 6 months after the CXL procedure, no further changes in visual performance, patient comfort or clinical appearance of the corneas were observed. At the 4-month recheck, corneal thickness was 1.2 mm OD and 1.46 mm OS. However, topical treatment with 5% sodium chloride ointment was discontinued due to irritation. Topical treatment was continued with cyclosporine 0.2% twice daily and ketorolac 0.5% once daily.

## RESULTS AND DISCUSSION

All four eyes included in this case report had persistent/recurrent corneal epithelial erosions present for at least 2 months prior to CXL treatment. These four eyes were comfortable and fluorescein negative 1 week following CXL treatment and remained so for the rest of the follow-up period: 17.5 months for case 1 and 6 months for case 2. No adverse effects of the CXL procedure, such as delayed epithelial healing, postprocedural pain or infection were observed. Pigmentation of the cornea was present prior to CXL in both patients and appeared to have progressed slightly 1 month after CXL in the second patient. Further progression of the corneal pigmentation was not observed in either patient while being treated with cyclosporine 0.2% twice daily OU.

The primary treatment goal, namely resolution of the corneal erosions and associated pain, was fulfilled, indicating that CXL may be a successful treatment alternative for dogs with bullous keratopathy. This result is consistent with the current literature, as various case series reported the effective use of CXL for the treatment of corneal oedema, endothelial decompensation and bullous keratopathy in humans.<sup>11,18–22</sup>

Corneal collagen cross-linking seems to have led to a subjective increase in corneal transparency in case 1 and to an objective, although not clinically significant, thinning of the cornea in case 2. The effect was temporary in both cases, which is consistent with the current clinical physician-based ophthalmic literature.<sup>11,21–23</sup>

Wollensak *et al.*<sup>24</sup> described a significant decrease in the swelling of the anterior corneal stroma after CXL in

*in vitro* pig eyes. A study by Sondergaard *et al.*<sup>3</sup> demonstrated a significant reduction in anterior stromal swelling pressure in porcine and human corneas after CXL *in vitro*, suggesting that CXL may reduce corneal swelling pressure *in vivo* as well, thereby reducing oedema and improving vision. The mechanism of this CXL-induced swelling pressure reduction is unknown. However, cross-linking between corneal collagen fibres has not been demonstrated after CXL, and it seems unlikely that the effects of CXL are limited to stromal collagen alone.<sup>25</sup> Hayes *et al.*<sup>2</sup> concluded that cross-links formed during riboflavin/UVA therapy likely occur at the collagen fibril surface and in the proteoglycan network surrounding the collagen fibres. Furthermore, swelling pressure reducing effects of CXL might also be mediated through modifying effects on the hydrophilic and negatively charged nature of the stromal glycosaminoglycans.<sup>25,26</sup> No convincing explanations regarding the temporary thinning effect of CXL on the cornea have been proposed in the scientific literature.

Current CXL protocols deliver the cross-linking effects to the superficial stroma<sup>1,24,27</sup> where the swelling potential is the lowest.<sup>28,29</sup> The dehydration of both corneas of case 2 with topical 70% glycerol solution immediately prior to CXL did not change the outcome compared to case 1 in terms of resolution of the erosions and associated pain nor in terms of corneal transparency and rehabilitation of vision. Finding ways to treat the posterior stroma and thereby preventing posterior corneal stromal swelling could potentially increase the effectiveness of CXL.

Corneal collagen cross-linking is less invasive compared to some of the surgical alternatives for the symptomatic treatment of bullous keratopathy in dogs such as thermokeratoplasty and conjunctival flap surgery, which cause significant anterior stromal and corneal surface fibrosis.<sup>12,17</sup>

If any conclusions can be drawn based on the two cases presented in this manuscript, it would be that currently the main indication for CXL treatment of bullous keratopathy in dogs is the treatment of persistent corneal oedema-induced epithelial erosions. The temporary and clinically insignificant decrease in corneal thickness does not justify the use of CXL for the sole purpose of increasing corneal transparency and improving vision. However, the presently used CXL protocols were developed for the treatment of progressive keratoconus in humans with a focus on treatment safety.<sup>1</sup> These protocols will likely need modification regarding CXL intensity and riboflavin concentration to fit both the dog cornea and to optimize the treatment of bullous keratopathy.

## DISCLOSURE

Simon Pot: None; Nicolin Gallhöfer: None; Ladina Walser-Reinhardt: None; Farhad Hafezi: None; Bernhard Spiess: None.

## REFERENCES

1. Spoerl E, Mrochen M, Sliney D *et al.* Safety of UVA-riboflavin cross-linking of the cornea. *Cornea* 2007; **26**: 385–389. Epub 2007/04/26.
2. Hayes S, Kamma-Lorger CS, Boote C *et al.* The effect of riboflavin/UVA collagen cross-linking therapy on the structure and hydrodynamic behaviour of the ungulate and rabbit corneal stroma. *PLoS ONE* 2013; **8**: e52860. Epub 2013/01/17.
3. Søndergaard AP, Ivarsen A, Hjortdal J. Reduction of stromal swelling pressure after UVA-riboflavin cross-linking. *Investigative Ophthalmology & Visual Science* 2013; **54**: 1625–1634.
4. Spoerl E, Wollensak G, Seiler T. Increased resistance of crosslinked cornea against enzymatic digestion. *Current Eye Research* 2004; **29**: 35–40.
5. Wollensak G, Spoerl E, Seiler T. Stress-strain measurements of human and porcine corneas after riboflavin-ultraviolet-A-induced cross-linking. *Journal of Cataract and Refractive Surgery* 2003; **29**: 1780–1785. Epub 2003/10/03.
6. Wollensak G, Spoerl E, Wilsch M *et al.* Keratocyte apoptosis after corneal collagen cross-linking using riboflavin/UVA treatment. *Cornea* 2004; **23**: 43–49. Epub 2004/01/01.
7. Mazzotta C, Balestrazzi A, Traversi C *et al.* Treatment of progressive keratoconus by riboflavin-UVA-induced cross-linking of corneal collagen: ultrastructural analysis by Heidelberg Retinal Tomograph II *in vivo* confocal microscopy in humans. *Cornea* 2007; **26**: 390–397. Epub 2007/04/26.
8. Dhaliwal JS, Kaufman SC. Corneal collagen cross-linking: a confocal, electron, and light microscopy study of eye bank corneas. *Cornea* 2009; **28**: 62–67. Epub 2008/12/19.
9. Wollensak G, Spoerl E, Seiler T. Riboflavin/ultraviolet-a-induced collagen crosslinking for the treatment of keratoconus. *American Journal of Ophthalmology* 2003; **135**: 620–627.
10. Iseli HP, Thiel MA, Hafezi F *et al.* Ultraviolet A/riboflavin corneal cross-linking for infectious keratitis associated with corneal melts. *Cornea* 2008; **27**: 590–594.
11. Ehlers N, Hjortdal J. Riboflavin-ultraviolet light induced cross-linking in endothelial decompensation. *Acta Ophthalmologica* 2008; **86**: 549–551. Epub 2008/06/10.
12. Gilger BC. Diseases and surgery of the canine cornea and sclera. In: Gelatt KN ed. *Veterinary Ophthalmology*, 4th edn. Blackwell Pub., Ames, IA, 2007; 690–752.
13. Spiess BM, Pot SA, Florin M *et al.* Corneal collagen cross-linking (CXL) for the treatment of melting keratitis in cats and dogs: a pilot study. *Veterinary Ophthalmology* 2013; doi: 10.1111/vop.12027 [Epub ahead of print]
14. Famose F. Evaluation of accelerated collagen cross-linking for the treatment of refractory deep keratitis in 8 dogs and 10 cats. Annual Meeting of the European College of Veterinary Ophthalmologists, Barcelona, 2013.
15. Hellander-Edman A, Makdoui K, Mortensen J *et al.* Corneal cross-linking in 9 horses with ulcerative keratitis. *BMC Veterinary Research* 2013; **9**: 128. Epub 2013/06/28.
16. Pot SA, Gallhofer NS, Matheis FL *et al.* Corneal collagen cross-linking as treatment for infectious and noninfectious corneal melting in cats and dogs: results of a prospective, nonrandomized, controlled trial. *Veterinary Ophthalmology* 2013; doi: 10.1111/vop.12090 [Epub ahead of print].
17. Michau TM, Gilger BC, Maggio F *et al.* Use of thermokeratoplasty for treatment of ulcerative keratitis and bullous keratopathy secondary to corneal endothelial disease in dogs: 13 cases (1994–2001). *Journal of the American Veterinary Medical Association* 2003; **222**: 607–612. Epub 2003/03/07.
18. Hafezi F, Dejica P, Majo F. Modified corneal collagen crosslinking reduces corneal oedema and diurnal visual fluctuations in Fuchs dystrophy. *British Journal of Ophthalmology* 2010; **94**: 660–661. Epub 2010/05/08.
19. Wollensak G, Aurich H, Wirbelauer C *et al.* Potential use of riboflavin/UVA cross-linking in bullous keratopathy. *Ophthalmic Research* 2009; **41**: 114–117. Epub 2009/01/06.
20. Ehlers N, Hjortdal J, Nielsen K *et al.* Riboflavin-UVA treatment in the management of edema and nonhealing ulcers of the cornea. *Journal of refractive surgery* 2009; **25**: S803–S806. Epub 2009/09/24.
21. Cordeiro Barbosa MM, Barbosa JB Jr, Hirai FE *et al.* Effect of cross-linking on corneal thickness in patients with corneal edema. *Cornea* 2010; **29**: 613–617. Epub 2010/05/12.
22. Ghanem RC, Santhiago MR, Berti TB *et al.* Collagen crosslinking with riboflavin and ultraviolet-A in eyes with pseudophakic bullous keratopathy. *Journal of Cataract and Refractive Surgery* 2010; **36**: 273–276. Epub 2010/02/16.
23. Greenstein SA, Shah VP, Fry KL *et al.* Corneal thickness changes after corneal collagen crosslinking for keratoconus and corneal ectasia: one-year results. *Journal of Cataract and Refractive Surgery* 2011; **37**: 691–700. Epub 2011/03/23.
24. Wollensak G, Aurich H, Pham DT *et al.* Hydration behavior of porcine cornea crosslinked with riboflavin and ultraviolet A. *Journal of Cataract and Refractive Surgery* 2007; **33**: 516–521. Epub 2007/02/27.
25. Klyce SD. UVA-riboflavin collagen cross-linking: a misnomer perhaps, but it works. *Investigative Ophthalmology & Visual Science* 2013; **54**: pii: 1635. doi: 10.1167/iops.13-11807.
26. Hodson S, Earlam R. The incorporation of gel pressure into the irreversible thermodynamic equation of fluid flow in order to explain biological tissue swelling. *Journal of Theoretical Biology* 1993; **163**: 173–180. Epub 1993/07/21.
27. Kohlhaas M, Spoerl E, Schilde T *et al.* Biomechanical evidence of the distribution of cross-links in corneas treated with riboflavin and ultraviolet A light. *Journal of Cataract and Refractive Surgery* 2006; **32**: 279–283. Epub 2006/03/28.
28. Dawson DG, Ubels JL, Edelhauser HF. Cornea and Sclera. In: *Adler's Physiology of the Eye*, 11th edn. (eds Levin LA, Nilsson SFE, Ver Hoeve J, Wu SM, Kaufman PL, Alm A) Saunders/Elsevier, Edinburgh, New York, 2011; 795. p. xii.
29. Meek KM, Leonard DW, Connon CJ *et al.* Transparency, swelling and scarring in the corneal stroma. *Eye (London, England)* 2003; **17**: 927–936. Epub 2003/11/25.