

Corneal Cross-Linking–Induced Stromal Demarcation Line

Theo Seiler, MD, PhD and Farhad Hafezi, MD

Purpose: Corneal collagen cross-linking by UVA/riboflavin (X-linking) represents a new method for the treatment of progressive keratoconus and currently is under clinical study. To avoid UVA irradiation damage to the corneal endothelium, the parameters for X-linking are set in a way that effective treatment occurs only in the first 300 μm of the corneal stroma. Here, X-linking not only strengthens the biomechanical properties of the cornea but also induces keratocyte apoptosis. To date, the effectiveness of treatment could be monitored only indirectly by postoperative follow-up corneal topographies or using corneal confocal microscopy. Here we describe a corneal stromal demarcation line indicating the transition zone between cross-linked anterior corneal stroma and untreated posterior corneal stroma. The demarcation line is biomicroscopically detectable in slit-lamp examination as early as 2 weeks after treatment.

Methods: X-linking was performed in 16 cases of progressive keratoconus, and corneas were examined biomicroscopically and by means of corneal topography and pachymetry before and after treatment.

Results: In 14 of 16 cases, a thin stromal demarcation line was visible at a depth of approximately 300 μm over the whole cornea after X-linking treatment.

Conclusion: This newly observed demarcation line may result from differences in the refractive index and/or reflection properties of untreated versus X-linked corneal stroma and represents an effective tool to biomicroscopically easily monitor the depth of effective X-linking treatment in keratoconus.

Key Words: corneal cross-linking, riboflavin, UVA, keratoconus, demarcation line

(*Cornea* 2006;25:1057–1059)

Keratoconus represents a disorder of the corneal stroma that is associated with decreased biomechanical strength of the tissue, probably caused by diminished intra- and interfibrillar cross-links of the collagen fibers.¹ Recently, a new method has

been developed for the treatment of progressive keratoconus, which currently is under clinical study: corneal collagen cross-linking with riboflavin/UVA (X-linking).^{2,3} Here, additional cross-links are formed using UVA and riboflavin as a chromophore. The method has been studied extensively in various animal models for years^{3–5} and was successfully applied in a phase 1 clinical trial for progressive keratoconus in humans.⁶ Basically, X-linking treatment markedly stiffens the cornea and increases the biomechanical strength by a factor of 1.4 in vivo in rabbit corneas and by a factor of 4.5 ex vivo in human corneas.^{3,7} To avoid potential irradiation damage to the corneal endothelium by UVA light, the technical parameters are set in a way that only the anterior 300 μm of the corneal stroma is treated. To date, the transition zone between X-linked and untreated corneal stroma could be visualized only using corneal confocal microscopy.⁸ Here we report biomicroscopic identification of a corneal stromal demarcation line that corresponds to this transition zone.

MATERIALS AND METHODS

Inclusion Criteria

Sixteen patients suffering from progressive keratoconus (age range, 18–39 years; mean age, 26.4 years) with maximal corneal K readings of 60 D and central corneal thickness of at least 400 μm were treated by corneal collagen X-linking with riboflavin/UVA. Inclusion criteria were the identification of progressive keratectasia in corneal topographies using both the Schwiegerling Z3 coefficient⁹ and an increase of maximal K-readings in several consecutive recordings over a period of up to 6 months, along with anamnestically reported deterioration of vision. Preoperative and postoperative examination included slit-lamp examination, best spectacle-corrected visual acuity (BSCVA), corneal topography and a pachymetric map (Pentacam; Oculus Instruments, Wetzlar, Germany), and applanation tonometry.

Preparation of 0.1% Riboflavin Solution

Dilute vitamin B₂-riboflavin-5-phosphate 0.5% (G. Streuli & Co., Uznach, Switzerland) with dextran T500 (Roth AG, Karlsruhe, Germany) was used to achieve a 0.1% riboflavin solution. The solution was protected from light and used within 24 hours.

Corneal Collagen Riboflavin/UVA–Cross-Linking (X-Linking)

The procedure was performed as described previously.⁶ In brief, topical anesthesia was applied before the procedure

Received for publication February 21, 2006; accepted April 26, 2006.

From the Institute for Refractive and Ophthalmic Surgery, Zurich, Switzerland.

The authors state that they have no proprietary interest in the products named in this article.

Reprints: Farhad Hafezi, MD, IROC, Institute for Refractive and Ophthalmic Surgery, Stockerstrasse 37, CH–8002 Zurich, Switzerland (e-mail: farhad.hafezi@iroc.ch).

Copyright © 2006 by Lippincott Williams & Wilkins

using tetracaine 1% and oxybuprocaine 0.4% eyedrops (Novartis Pharma, Bern, Switzerland).

The corneal epithelium was mechanically removed with a diameter of 6-mm by using a blunt knife, and riboflavin 0.1% solution was instilled repeatedly for approximately 20 minutes. Penetration of the cornea and presence of riboflavin in the anterior chamber (riboflavin shielding) was monitored with slit-lamp examination. UVA irradiation was performed using an optical system (Köhler illumination) with a light source consisting of an array of 7 UV diodes (365 nm; Nichia, Nuernberg, Germany) with a potentiometer in series to allow for regulation of voltage. Before treatment, intended irradiance of 3 mW/cm² surface irradiance (5.4 J/cm² surface dose) was calibrated using a UVA meter (LaserMate-Q; LASER 2000, Wessling, Germany) at a working distance of 1 cm. Irradiance was performed for 30 minutes by using 3 mW/cm², corresponding to a dose of 5.4 J/cm². During treatment, riboflavin solution was applied every 5 minutes to saturate the cornea with riboflavin, and drops of physiological salt solution were applied every 2 minutes to moisten the cornea. After the treatment, a bandage contact lens soaked with preservative-free antibiotic (ofloxacin) was applied until complete closure of the corneal epithelium, followed by application of fluorometholone eyedrops twice daily for 6 weeks.

RESULTS

Postoperative healing was uneventful in all cases. In accordance with previously published data,⁶ we detected no side effects of the anterior or posterior segment: in particular, corneal endothelium showed no signs of cytotoxic damage

and lens transparency, and intraocular pressure remained unchanged.

However, in 14 of 16 patients, we identified a demarcation line in the deep corneal stroma detectable by slit-lamp examination (Fig. 1). In the central corneal stroma, the line can be identified at approximately 60% corneal depth (Fig. 1B and C). The line is best identified with a thin slit and high illumination levels by using a slit lamp that provides high levels of white light. In the corneal periphery, the line gradually adopts a conical shape because of the increasing total corneal thickness (Fig. 1D). The line becomes visible as early as 2 weeks after treatment and was not present before treatment (n = 16).

DISCUSSION

When treating patients with corneal X-linking, special emphasis has to be taken to ensure protection of the corneal endothelium from potential UVA irradiation damage. The stromal depth of effective X-linking treatment depends on the concentration of riboflavin solution and the intensity of UVA light. The ideal riboflavin concentration and UVA intensity levels were identified through dose/concentration assays in vitro and in various animal models.^{2,3,5,10-13} The parameters currently used in humans (international multicenter clinical phase 2 study monitored by us) are 0.1% riboflavin solution and 3 mW/cm² of UVA. It has been shown unambiguously that, at these settings, the effect of X-linking is limited to the anterior 300 μ m of the cornea.⁴ Furthermore, only patients with a central corneal thickness of at least 400 μ m are subjected to this treatment.

Besides induction of additional cross-links between collagen fibers, the X-linking treatment induces various other

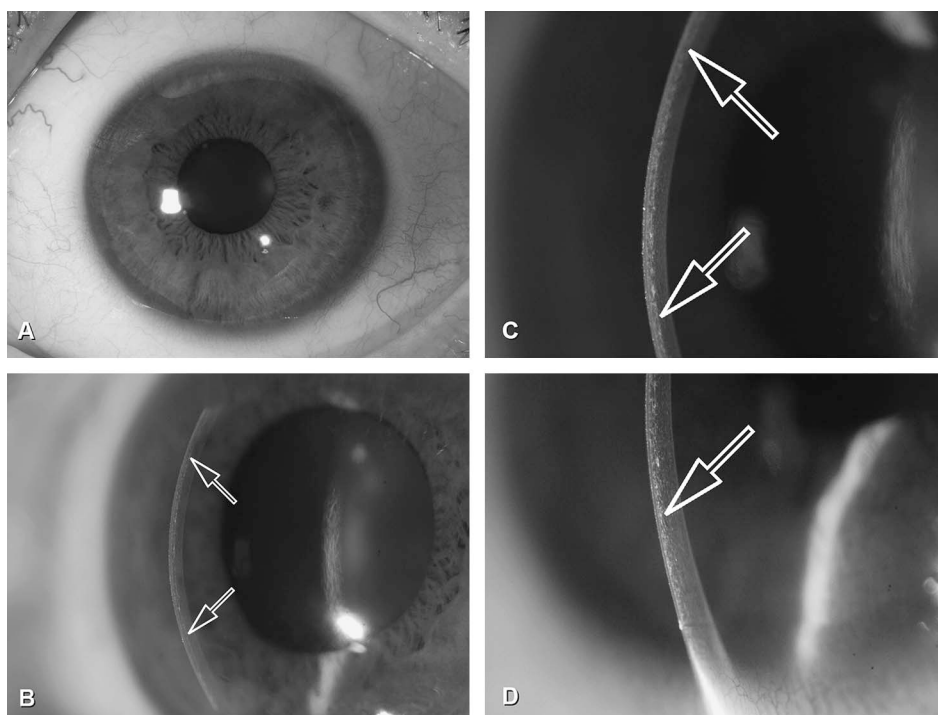


FIGURE 1. Corneal demarcation line after X-linking. A, Regular aspect of the cornea at 2 weeks after X-linking (top left). B, Demarcation line (arrows) lies in a depth of approximately 300 μ m. The conical shape of the line is explained by the increasing thickness of the cornea in the periphery. C, In the central cornea, the line (arrows) can be identified at approximately 60% corneal depth. D, In the (thicker) periphery, the line (arrow) lies at approximately 30% to 40%.

stromal changes: Wollensak et al⁴ have shown induction of keratocyte apoptosis in the rabbit cornea after cross-linking treatment. However, corneal transparency and thickness remained unchanged and keratocyte apoptosis also occurs after photorefractive keratectomy (PRK), laser in situ keratomileusis (LASIK), and even corneal abrasion.¹⁴

In consequence, after X-linking treatment, one should differentiate between the treated anterior corneal stroma and the untreated posterior corneal stroma. The positive effect of corneal X-linking on corneal biomechanics can be monitored indirectly using corneal topography. However, until recently, there was no method available to directly monitor the effect of corneal X-linking on the anterior corneal stroma.

In a recent study, Caporossi et al⁸ performed confocal microscopy analyses in humans after X-linking. Interestingly, they in vivo detected the effective depth of treatment by identifying distinct vertical and lateral transition areas at a depth of 270 to 330 μm . Here, the anterior (treated) stroma showed edema with only a few keratocyte nuclei and poor reflectivity, whereas the posterior (untreated) stroma showed regular keratocyte population and normal reflectivity. Keratocyte repopulation of the treated stroma started at 1 month after treatment and was completed at 6 months after treatment. Corneal endothelium showed regular morphology up to 6 months after treatment.

In accordance with these findings, we report identification of a corneal stromal demarcation line that becomes visible at 2 weeks after X-linking treatment in a depth of approximately 300 μm . To our knowledge, the presence of such a demarcation line after X-linking has not been reported to date and ultimately implies either a change in the refractive index and/or reflection properties of treated versus untreated cornea. From the findings by Caporossi et al,⁸ we suggest that this line actually represents the demarcation line between cross-linked and untreated cornea.

The demarcation line described here represents, besides corneal topography, a direct clinical sign to detect the effect of X-linking in the cornea and, in addition, may help to clinically estimate the thickness of the stromal layer that underwent X-linking.

In conclusion, biomicroscopic identification of this line represents a simple and effective clinical tool to easily monitor the effective depth of X-linking treatment.

ACKNOWLEDGMENTS

The authors thank Peter Baer, ophthalmic photographer at the Department of Ophthalmology, University Hospital Zurich, Switzerland, for skillful photos of the demarcation line.

REFERENCES

1. Cannon DJ, Foster CS. Collagen crosslinking in keratoconus. *Invest Ophthalmol Vis Sci*. 1978;17:63–65.
2. Spoerl E, Seiler T. Techniques for stiffening the cornea. *J Refract Surg*. 1999;15:711–713.
3. Spoerl E, Huhle M, Seiler T. Induction of cross-links in corneal tissue. *Exp Eye Res*. 1998;66:97–103.
4. Wollensak G, Spoerl E, Wilsch M, et al. Keratocyte apoptosis after corneal collagen cross-linking using riboflavin/UVA treatment. *Cornea*. 2004;23:43–49.
5. Wollensak G, Spoerl E, Reber F, et al. Corneal endothelial cytotoxicity of riboflavin/UVA treatment in vitro. *Ophthalmic Res*. 2003;35:324–328.
6. Wollensak G, Spoerl E, Seiler T. Riboflavin/ultraviolet-a-induced collagen crosslinking for the treatment of keratoconus. *Am J Ophthalmol*. 2003;135:620–627.
7. Wollensak G, Spoerl E, Seiler T. Stress-strain measurements of human and porcine corneas after riboflavin-ultraviolet-A-induced cross-linking. *J Cataract Refract Surg*. 2003;29:1780–1785.
8. Caporossi A, Baiocchi S, Mazzotta C, et al. Parasurgical therapy for keratoconus by riboflavin-ultraviolet type A rays induced cross-linking of corneal collagen: preliminary refractive results in an Italian study. *J Cataract Refract Surg*. 2006;32(5):837–845.
9. Schwiegerling J, Greivenkamp JE. Keratoconus detection based on videokeratographic height data. *Optom Vis Sci*. 1996;73:721–728.
10. Wollensak G, Spoerl E, Seiler T. [Treatment of keratoconus by collagen cross linking]. *Ophthalmologie*. 2003;100:44–49.
11. Wollensak G, Spoerl E, Wilsch M, et al. Endothelial cell damage after riboflavin-ultraviolet-A treatment in the rabbit. *J Cataract Refract Surg*. 2003;29:1786–1790.
12. Spoerl E, Schreiber J, Hellmund K, et al. [Studies on the stabilization of the cornea in rabbits]. *Ophthalmologie*. 2000;97:203–206.
13. Spoerl E, Huhle M, Kasper M, et al. [Increased rigidity of the cornea caused by intrastromal cross-linking]. *Ophthalmologie*. 1997;94:902–906.
14. Wilson SE. Role of apoptosis in wound healing in the cornea. *Cornea*. 2000;19 (3 Suppl):S7–S12.