

In Vivo Confocal Microscopy after Corneal Collagen Crosslinking

COSIMO MAZZOTTA, MD, PhD,¹ FARHAD HAFEZI, MD, PhD,² GEORGE KYMIONIS, MD, PhD,³
STEFANO CARAGIULI, MD,¹ SOOSAN JACOB, MD, PhD,⁴ CLAUDIO TRAVERSI, MD,¹
STEFANO BARABINO, MD,⁵ AND BRADLEY J. RANDLEMAN, MD⁶

ABSTRACT In vivo confocal microscopy (IVCM) findings of 84 patients who had undergone conventional epithelium-off corneal collagen crosslinking (CXL) and accelerated CXL (ACXL) were retrospectively reviewed. Analysis confirmed that despite a significant decrease in the mean density of anterior keratocytes in the first 6 postoperative months, cell density after CXL and ACXL returned to baseline values at 12 months. The demarcation lines observed after treatments represent an expression of light-scattering (reflectivity changes) through different tissue densities. Temporary haze

of the anterior-mid stroma after conventional CXL represents an indirect sign of CXL-induced stromal collagen compaction and remodeling. IVCM showed that treatment penetration varies to some extent, but that the endothelium is not damaged and is correlated with CXL biomechanical effects. IVCM of limbal structures shows no evidence of pathological changes. Regeneration of subepithelial and stromal nerves was complete 12 months after the operation with fully restored corneal sensitivity and no neuro-dystrophic occurrences. IVCM allowed detailed high magnification in vivo micromorphological analysis of corneal layers, enabling the assessment of early and late corneal modifications induced by conventional and accelerated CXL. IVCM confirms that CXL is a safe procedure, which is still undergoing development and protocol adjustments.

KEY WORDS accelerated crosslinking (ACXL), corneal collagen crosslinking (CXL), crosslinking, in vivo confocal microscopy (IVCM), keratoconus

Accepted for publication April 2015.

From ¹Siena Crosslinking Center, Siena University Hospital, Siena, Italy, ²Department of Ophthalmology, Geneva University Hospitals, Geneva, Switzerland, ³Institute of Vision and Optics, University of Crete, Heraklion, Greece, and Bascom Palmer Eye Institute, University of Miami, Miami, FL, USA, ⁴Agarwal's Eye Hospital and Eye Research Centre, Chennai, India, ⁵Ophthalmic Operative Unit, Geoa University, Genoa, Italy, ⁶Emory Eye Center and Emory Vision, Atlanta, GA, USA.

Authors' roles:

Drs. Mazzotta, Traversi, Caragiuli, and Barabino: conception and design.

Drs. Mazzotta, Traversi, and Caragiuli: data collection and writing of article.

Drs. Mazzotta and Traversi: qualitative and quantitative analysis and interpretation.

Drs. Hafezy, Kymionis, Jacob, and Randleman: critical revision of the article and retrospective review of the images.

Dr. Barabino: statistical expertise.

All Authors reviewed and approved the submitted manuscript.

Financial support: None.

The authors have no commercial or proprietary interest in any concept or product discussed in this article.

Single-copy reprint requests to Cosimo Mazzotta, MD, PhD (address below).

Corresponding author: Cosimo Mazzotta, MD, PhD, Siena Crosslinking Center, S. Pertini street, number 7, Siena, Italy, 53100. Tel: +39 0577 51394. Fax: +39 0577 356618. E-mail address: cgmazzotta@libero.it

I. INTRODUCTION

Keratoconus is an ectatic disease of the cornea characterized by biochemical and biomechanical instability of stromal collagen, leading to a reduction of corneal thickness, variation in posterior and anterior corneal curvatures, and progressive deterioration of visual acuity due to irregular astigmatism.^{1,2} The advent of corneal collagen crosslinking in the last decade has transformed the conventional therapy of keratoconus (previously, a lifetime of hard contact lenses wear, at best, or a corneal transplant, at worst), improving conservative treatment and thus reducing the necessity of lamellar and penetrating corneal graft.³⁻⁶

Conventional riboflavin UV-A crosslinking represents an evolving therapy for conservative treatment of progressive keratoconus and secondary corneal ectasia, as it can increase biomechanical corneal resistance and intrinsic anticollagenase activity.^{7,8} The physiochemical basis of conventional epithelium-off corneal crosslinking (CXL) lies in the photodynamic type I-II reactions induced

OUTLINE

- I. Introduction
- II. Methods
 - A. Patients
 - B. Procedures
- III. In Vivo Confocal Microscopy Findings
 - A. Stromal Wound Healing and Demarcation Lines
 - B. Limbus and Epithelium
 - C. Nerves
 - D. Endothelium
- IV. Discussion

by the interaction between 0.1% riboflavin molecules absorbed in corneal tissue and UV-A rays delivered at 3 mW/cm² for 30 minutes (5.4 J/cm² energy dose), releasing reactive oxygen species that mediate crosslink formation between and within collagen fibers.⁹⁻¹¹

A series of nonrandomized and randomized clinical trials have provided evidence that conventional CXL with epithelium removal today is a scientifically well-supported treatment with a largely documented long-term efficacy in stabilizing progressive keratoconus and secondary ectasia.^{5,6,11-14} Since the conventional CXL procedure requires a long time (about 1 hour), new accelerated crosslinking (ACXL) treatment protocols, based on the physical principles stated in Bunsen-Roscoe's law of reciprocity, are now under investigation. These will shorten treatment time, improve patient comfort, and reduce hospital waiting lists.¹⁵⁻²¹

Bunsen-Roscoe's law established that photochemical reactions (including the photochemical process behind CXL) depend on absorbed UV-A energy (E), and their biological effect is proportional to the total energy dose delivered into the tissue.¹⁸⁻²² According to the "equal-dose" physical principle, 10 mW/cm² for 9 min, 18 mW/cm² for 5 min, 30 mW/cm² for 3 min or 45 mW/cm² for 2 min at constant dose E of 5.4 J/cm² may have the same photochemical impact as conventional CXL at 3 mW/cm² for 30 minutes.^{18,22}

The safety and corneal changes achieved by conventional CXL and ACXL for conservative keratoconus treatment have been directly evaluated in vivo in humans by laser scanning in vivo confocal microscopy (IVCM) of the cornea.²³⁻³⁰

First described by Marvin Minsky in the last century,³¹ IVCM is a noninvasive method of examining the living human cornea in healthy and pathological conditions, making it a powerful clinical and research tool.³² The basic principle of IVCM involves the optical sectioning of a (relatively) thick, light-scattering object, such as the cornea. Light is passed through an aperture and focused by an objective lens onto a small area of the examined specimen. The light reflected from the specimen then passes through a second objective lens and focuses on a second aperture that is arranged so that out-of-focus light is eliminated.

Because the illumination and detection paths share the same focal plane, the term "confocal" is used. The ability of this system to discriminate between light that is not on the confocal plane yields images of higher lateral and axial resolution, even if the system is limited by its small field of view. The signals produced by reflected light are detected by electronic detectors such as cameras based on a charge-coupled device (CCD camera). Video and/or digital image capture systems are available, with image acquisition rates of at least 25 frames per second.

Our confocal analyses were all performed with The HRT II, Rostock Cornea Module, Heidelberg Engineering, GmbH, Germany, a coherent light in vivo confocal microscope using Helium Neon diode laser source at 670-nm red wavelength. The illumination sources are thus single-wavelength coherent light images creating greater contrast with lateral resolution at 1-2 μ m and variable depth resolution (z-axis) with a quoted range of 4-25 μ m.³³

Examining the full thickness of the living human cornea at the cellular level, IVCM has revolutionized the understanding of the postoperative corneal changes induced by photodynamic riboflavin UV-A-induced CXL with a precise spatiotemporal definition of corneal repair processes and stromal wound healing in both progressive keratoconus and secondary corneal ectasias (post-laser-assisted in situ keratomileusis [LASIK] and radial keratotomy [RK]).^{7,8,24-26,28,29,34,35}

Although there has been a recent trend toward quantitative studies³³ using IVCM, readily reproducible methods and reference values for quantitative assessment still need to be standardized. Most studies report lower interobserver repeatability compared with intraobserver repeatability, and observer experience is known to be an important factor. In this paper, we describe qualitative observations from our IVCM basic studies of the cornea after CXL.^{23,24,26,36}

IVCM allowed a detailed high magnification in vivo microstructural analysis of corneal layers, enabling the assessment of early and late corneal modifications induced by these innovative treatments and identification of postoperative complications.^{25,34,37,38}

II. METHODS

A. Patients

We retrospectively reviewed the records of 84 patients who underwent corneal crosslinking procedures for keratoconus over a 10-year period at the Department of Ophthalmology of Siena University, Italy.^{4-6,15-17,23,24,26,36,41} The studies were approved by the Siena University Institutional Review Board and conformed to the ethical principles for medical research according to the Helsinki Declaration.

Patients included in the CXL and ACXL treatment protocols were affected by progressive keratoconus with minimum corneal thickness at least of 400 μ m. Parameters considered to establish keratoconus progression were: worsening of UDVA/CDVA >0.1 Snellen lines, increase of SPH/CYL >1.00 D, increase of maximum K reading

>1 D, reduction of the thinnest point measured by AC OCT optical pachymetry $\geq 10 \mu\text{m}$, clear cornea at biomicroscopic examination, absence of reticular dark microstriations at scanning laser IVCM.

Of the 84 patients:

- 1) 44 underwent conventional CXL $3\text{mW}/\text{cm}^2$.^{5,26}
- 2) 20 underwent high-fluence ACXL at $30\text{mW}/\text{cm}^2$ (10 eyes with pulsed light and 10 eyes with continuous light UV-A exposure).^{15,16}
- 3) 10 underwent transepithelial crosslinking (TE-CXL) at $3\text{mW}/\text{cm}^2$.³⁶
- 4) 10 underwent transepithelial accelerated crosslinking (TE-ACXL) at $45\text{mW}/\text{cm}^2$.⁴¹

In the retrospective review of the records, a 24-month follow-up was established to be relevant from a microstructural viewpoint for each group, as that was the maximum follow-up available for recent ACXL procedures, even though longer follow-up was available for CXL patients in the Siena Eye Cross Study and TE-CXL patients in the Siena CrossLinking Evolution Study.^{5,16,36}

B. Procedures

All patients had been examined postoperatively by means of scanning laser IVCM with the Heidelberg Retina Tomograph II (HRT II), Rostock Cornea Module (RCM; Heidelberg Engineering, GmbH, Germany), analyzing stromal wound healing, the demarcation lines, corneal limbus, epithelium, nerves, and endothelium, both in conventional CXL and TE-CXL treatment modalities.^{24-26,30,36,39-41} Although our IVCM analysis was essentially qualitative, since the HRT II-RCM confocal microscope has a proprietary software for manual analysis of cell densities, pre- and postoperative keratocyte density evaluations were included at the 24-month follow-up examination.

IVCM examinations were performed by the same operator (C.M.) and manual quantitative analysis of keratocytes was attempted twice, first by the examiner and a then by an expert observer (C.T.). Two consecutive section images were taken at a depth of $150 \mu\text{m}$ (measured from the epithelial surface) to subjectively estimate the pre- and post-operative anterior stromal cell density. Stromal depth for quantitative analysis was established at $150 \mu\text{m}$ according to demarcation line depth and CXL-induced photo-oxidative damage, including the anterior stroma in each procedure. Manual analysis of keratocyte density, expressed as cell density per unit area, was performed in 24 eyes of conventional CXL, 20 eyes of ACXL, 10 eyes of TE-CXL, and 10 eyes of TE-ACXL treatments, respectively, marking each clearly defined cell or nucleus in a predefined mm^2 rectangular frame. Paired-*t* test was used for the statistical analysis.

III. IN VIVO CONFOCAL MICROSCOPY FINDINGS

A. Stromal Wound Healing and Demarcation Lines

In the field of CXL therapy (in both epithelium-off and transepithelial modalities),²³⁻²⁶ corneal in vivo human pilot micromorphological studies have become an integral part of

the basic studies of crosslinking therapy for keratoconus and secondary corneal ectasia.^{23,24,26} IVCM scans in conventional CXL procedures provided the first in vivo demonstration in humans that the cytotoxic effects of corneal collagen CXL with the standard UV-A dose of $3\text{mW}/\text{cm}^2$ ($5.4\text{J}/\text{cm}^2$) for 30 minutes were concentrated in the first $300 \mu\text{m}$ of the corneal stroma (about $350 \mu\text{m}$ measured from the epithelial surface), as evidenced by keratocyte loss (apoptosis [Figure 1A]). This finding confirmed the preclinical ex vivo and in vivo studies on animal models provided by Seiler, Wollensak, and Spoerl.⁴²⁻⁴⁵

IVCM detected the disappearance of keratocytes from the anterior and intermediate stroma due to apoptosis and photonecrosis phenomena in the early (1-6 months) and late (after 6 months) postoperative period. Keratocyte apoptosis associated with “lacunar” or “spongy” honeycomb-like edema represented the most relevant corneal changes detected in the early postoperative period after CXL both in conventional and accelerated procedures.^{24-26,28,29}

In TE-CXL, the apoptotic phenomenon was less evident, unevenly distributed under Bowman’s lamina and the anterior stroma (generally under $100 \mu\text{m}$ measured from the epithelial surface). It was superficial and inhomogeneous due to the limited penetration of UV-A photons across the epithelium that were left in situ and saturated by 0.1% riboflavin. This microstructural finding, in its intrinsic significance, is consistent with poor TE-CXL penetration. Keratocyte apoptosis in the first 3 postoperative months was invariably associated with stromal edema.

Early postoperative keratocyte apoptosis was common in conventional CXL (Figure 1A), TE-CXL (Figure 1B), ACXL with continuous light (Figure 1C), and ACXL with pulsed light (Figure 1D), representing different depths and intensities based on the absence or presence of the epithelium and on different UV-A power settings. The intensity of corneal edema increased linearly with intensifying UV-A power simultaneously with the reflectivity of extracellular tissue surrounding the edematous lacunae.^{24-26,29,36}

Stromal edema tends to persist after treatment for 1-3 months and is rarely observed at the 6th postoperative month, decreasing over time with topical steroid therapy. Postoperative stromal edema was associated with significant keratocyte loss in the first month and a dense network of hyper-reflective extracellular tissue described as “trabecular patterned stroma,” as seen in Figure 1A, C, and D.^{24-26,28,46}

Hyper-reflective or bright microparticles (keratocyte apoptotic bodies) were visible, together with elongated processes of activated keratocytes that sometimes appeared assembled in cellular clusters immersed in a dense extracellular trabecular mesh. Hyper-reflective “needle-shaped microbands” or microstriate reflections are commonly detectable both in conventional CXL and ACXL at different stromal depths, as shown in confocal scans (Figure 2A and B).^{24-26,36}

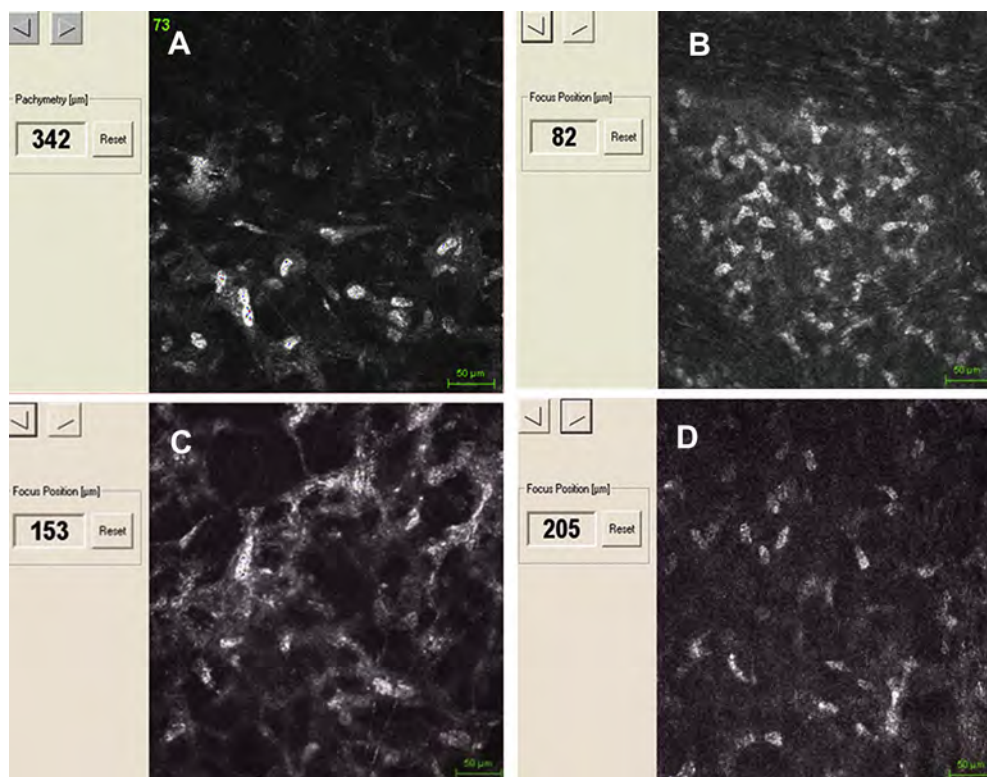


Figure 1. Demarcation lines occurring with various techniques. A: Conventional CXL shows a penetration of keratocyte apoptosis at 350 μm measured from epithelial surface. B: TE-CXL shows a limited apoptosis under 100 μm . ACXL with continuous light shows keratocyte apoptosis at 150 μm (C) and ACXL with pulsed light at 200 μm (D).

IVCM demonstrated in vivo in humans a progressive repopulation of the edematous anterior-mid stroma devoid of keratocytes (Figure 3A). Keratocyte repopulation was observed between the 2nd and the 3rd postoperative months (Figure 3B), centripetally from the non-irradiated peripheral area (beyond 8-9 mm diameter) and from the deeper stromal layers. Repopulation is incomplete at the 6th month (Figure 3C) and returns to baseline 12 months postoperatively (Figure 3D), as documented by gradual reduction of edema and progressive reappearance of activated cell nuclei.^{24-26,36}

Although the keratocyte repopulation process was evident by qualitative analysis in pilot IVCM studies,²³⁻²⁶ early quantitative studies demonstrated that average postoperative cell density in the anterior-mid stroma was reduced after 6 months without changes in posterior deep stroma beyond 300 μm .²⁹ Recent quantitative analysis

confirmed a significant decrease in the mean anterior postoperative keratocyte density at 1, 3, and 6 months with a return to baseline values at 12 months postoperatively.⁴⁷ Our quantitative data at 24 months showed a statistically significant reduction of keratocyte density in the anterior stroma at a depth of 150 μm in the first 6 postoperative months (both in conventional CXL and ACXL ($P \leq .01$)) with a return to baseline values at 12 months postoperatively, without statistically significant differences at 12 and 24 months ($P = .88$). (See Table 1.)

A variable increase in density of the extracellular matrix is typical after conventional CXL, particularly evident on IVCM until the 6th postoperative month, being seen as hyper-reflective tissue surrounding keratocyte nuclei. This appearance may last for 6-12 months and is variable, inhomogeneous, and frequently associated with microstriate reflections from the early postoperative period.^{24-26,36}

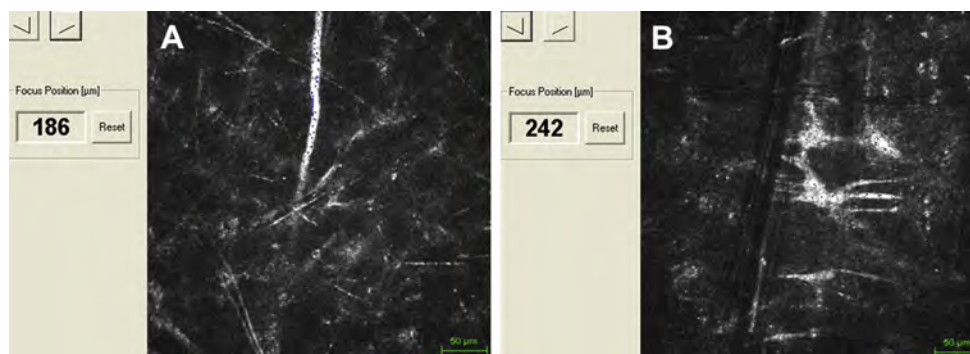


Figure 2. Hyper-reflective "needle-shaped micro-bands" or microstriate reflections and activated keratocytes with elongated membrane processes are detectable in the early postoperative period (1-6 months) both in conventional CXL (A) and ACXL (B) at different stromal depths.

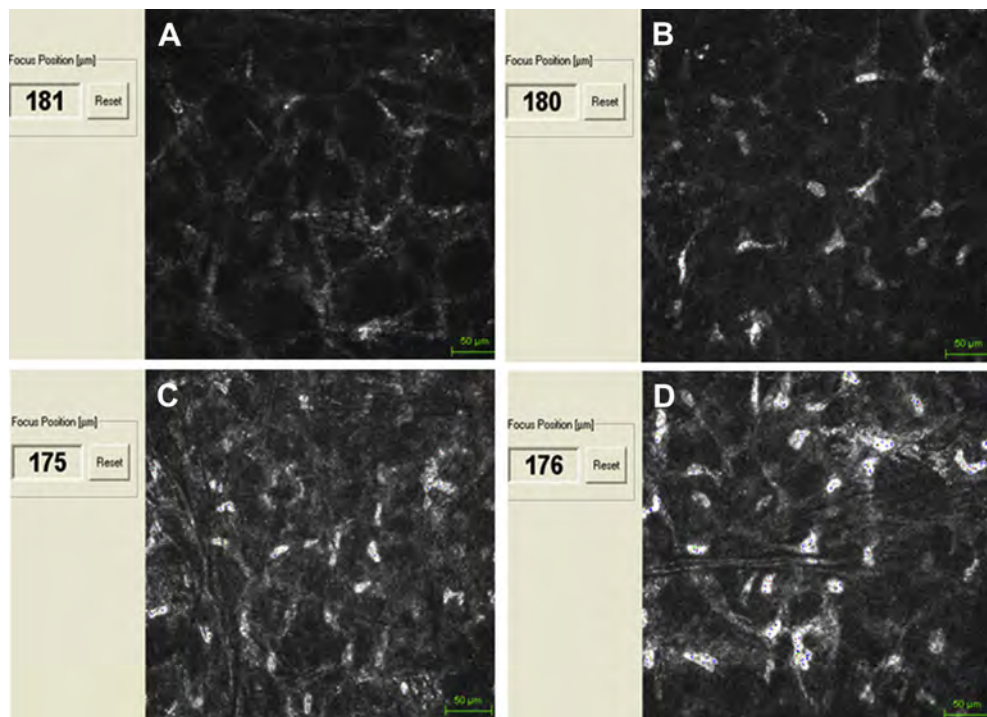


Figure 3. IVCM after conventional CXL demonstrated in vivo in humans keratocyte apoptosis followed by progressive repopulation of the anterior-mid stroma. Lacunar edema is visible in the first postoperative month with trabecular patterned hyperdense tissue surrounding edematous areas, entrapping apoptotic keratocyte bodies (A). At the 3rd postoperative month, stromal edema was reduced and keratocyte repopulation began, confirmed by the presence of keratocyte-activated nuclei (B). Six months after treatment, edema disappeared, followed by hyper-reflective extracellular matrix and cell repopulation (C). One year after treatment, anterior-mid stroma was repopulated by keratocytes and surrounded by dense extracellular collagen tissue (D).

The presence of hyper-reflective tissue was also common in ACXL with continuous and pulsed light with an average depth of less than 200 μm (measured from the epithelial surface [Figures 1C and D]).²⁹

After TE-CXL treatments that demonstrated an uneven, variable and superficial keratocyte apoptosis with a maximum depth of 100 μm measured from the epithelial surface, no relevant changes occurred in density of extracellular matrix, and no microstriate reflections were detected (Figure 1B).^{24-26,28}

The common hyperdensity (haze) of anterior-mid stroma after CXL and ACXL in most cases represents a transient sign of CXL-induced stromal collagen modifications, as demonstrated by in vivo postoperative corneal densitometry analysis.⁴⁸ Such modifications (anterior-mid stromal collagen compaction and remodeling) may often be visible on biomicroscopy as circular or

oval areas (generally corresponding to epithelial abrasion diameter) of denser tissue. Aside from an initial glare disability for 6-8 weeks, this does not affect final visual acuity.^{37,49} Collagen modifications may last in some patients (usually those with strong postoperative edema at the time of contact lens removal) past 6 months, generally disappearing after 12 months. IVCM analysis demonstrated a hyper-reflective extracellular tissue surrounding activated keratocyte nuclei and variable stromal edema (Figures 4A and B).^{24-26,36,50}

The activated keratocytes migrating from the periphery to the center of the cornea to repopulate the anterior-mid stroma²⁴ did not contain α -smooth muscle actin (α -SMA)⁵¹ and did not exhibit a myofibroblast phenotype.¹³

Haze after CXL differed in its clinical appearance from haze after excimer laser photorefractive keratectomy. The former is a dust-like change in the corneal stroma to the

Table 1. Quantitative analysis of keratocyte density after CXL, ACXL, TE CXL and TE ACXL

Keratocyte/mm ² 100 μm depth	Pre op	1 m	6 m	12 m	24 m
CXL 24 eyes	588 \pm 39	no	444 \pm 38	589 \pm 34	622 \pm 44
ACXL 20 eyes	464 \pm 72	no	359 \pm 34	450 \pm 40	446 \pm 39
TE CXL 10 eyes	502 \pm 42	489 \pm 30	511 \pm 42	601 \pm 35	599 \pm 41
TE ACXL 10 eyes	699 \pm 35	594 \pm 32	690 \pm 65	804 \pm 69	769 \pm 52

CXL, conventional CXL 3mW/cm²; ACXL, accelerated crosslinking 30 mW/cm²; TE CXL, transepithelial crosslinking 3 mW/cm²; TE ACXL, transepithelial accelerated crosslinking 45 mW/cm².

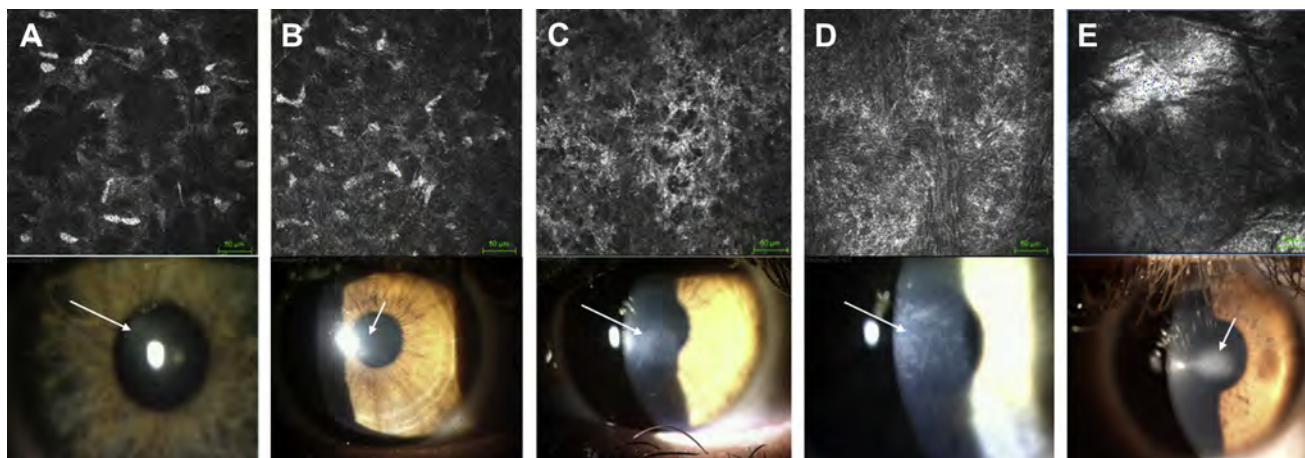


Figure 4. Hyperdensity (haze) of anterior-mid stroma after conventional CXL at biomicroscopic examination represents a sign of the CXL-induced stromal collagen compaction. This clinical aspect may last for over 6 months, generally disappearing after 12 months, and on IVCM corresponds to hyper-reflective extracellular tissue surrounding keratocyte nuclei (A and B). Haze after CXL represents a central, paracentral, or diffuse corneal opacity (scar) at different intensity. It represents a rare complication of conventional CXL and on IVCM is generally associated with the presence of hyper-reflective tissue devoid of cells (C-E).

mid-stromal demarcation line, whereas the latter has a typical reticulated subepithelial opacity unevenly involving the anterior stroma.⁵² The haze has been correlated with the depth of CXL into the stroma, as well as the amount of corneal edema and keratocyte loss.^{25,53} Scheimpflug densitometry and slit lamp assessment of the cornea after CXL showed a significant postoperative increase in haze.⁴⁹ The increase peaked at 1 month and plateaued between 1 and 3 months. Between the 3rd and 6th months, the cornea began to clear and there was a significant decrease in CXL-associated corneal haze. The haze usually does not require treatment, although some cases require low-dose short-term (1-3 months) steroid medication. Haze measurements continue to decrease from 6 months to 1 year postoperatively. Typically, late permanent scarring should be differentiated from the early postoperative temporary haze,⁵⁴ which does not negatively affect vision.

Permanent haze after CXL^{25,38} should be considered if a dense white central or paracentral corneal opacity (scar) develops that lasts for over 12 months, is unresponsive to topical steroid therapy, and negatively affects visual acuity. It is a rare complication of conventional CXL, which is variably reported in the literature.⁵³ On IVCM, it is characterized by the presence of hyper-reflective fibrotic tissue devoid of cells that may assume different intensities depending on the clinicopathological severity (Figure 4C, D, and E).

Risk factors for the development of permanent corneal haze after CXL include: uncontrolled intraoperative stromal dehydration leading to intraoperative corneal thickness reduction; thin corneas with minimum corneal thickness under 400 μm at the time of inclusion in the treatment protocol; age older than 35 years; the presence of activated keratocytes in the anterior stroma on preoperative IVCM; forwarded defocus of UV-A source on the corneal plane; lack of administration of riboflavin 0.1% solution during UV-A irradiation, or excessive intraoperative riboflavin-dextran

20% solution administration (causing intraoperative stromal dehydration); patient noncompliance with postoperative therapy; postoperative infections or therapeutic contact lens intolerance; and hypoxia leading to stromal edema and inflammatory response intensification.^{13,25,38,53,55} In our experience, the presence of Langerhans cells seen on IVCM after therapeutic contact lens removal is a prognostic factor for potential development of permanent haze and is an indication for intensive topical steroid therapy.

Other possible predisposing factors to early post-operative haze development after conventional CXL and ACXL include preoperative markedly visible Vogt's striae and corneal scars visible on slit lamp examination.

The anterior-mid stromal transient haze visible in the first 3-6 months after conventional and accelerated CXL rarely lasts over 12 months.¹⁴ Haze formation after CXL may be a result of backscattered and reflected light, which decreases corneal transparency.⁵⁶

The demarcation line observed after conventional CXL and ACXL represents an expression of light-scattering (reflectivity changes) through different tissue densities, underlying the transition from an early edematous area devoid of cells (stromal edema and apoptosis spreading at IVCM \pm 20 microns) to an area unreached by UV radiation regularly populated by cells. The deep corneal stroma beyond 350 μm measured from the epithelial surface in conventional CXL, 200 μm measured from the epithelial surface in continuous light ACXL, 250 μm measured from the epithelial surface in pulsed light ACXL, 100 μm in TE-CXL and TE-ACXL, did not undergo tissue changes other than vertical demarcation lines.^{26,30,57}

The depth of demarcation lines summarized in Table 2 can be reasonably considered as an expression of CXL-induced photo-oxidative damage penetration correlating with its biochemical and biomechanical effects, and functional visual acuity (including changes of refraction index of stromal tissue).^{36,48}

Table 2. Demarcation line depth

CXL Treatments 84 eyes	Conventional CXL 44 eyes 3 mW	C-light ACXL 10 eyes 30 mW	P-light ACXL 10 eyes 30 mW	TE CXL 10 eyes 3 mW	TE ACXL 10 eyes 45 mW
Average demarcation line depth (measured from epithelial surface)	350 ± 20 µm	200 ± 20 µm	250 ± 20 µm	100 ± 20 µm	100 ± 20 µm

*Average epithelial thickness: 50 ± 10 µm.

CXL, conventional crosslinking; C-light ACXL, continuous light accelerated crosslinking; P-light ACXL, pulsed light accelerated crosslinking; TE CXL, transepithelial crosslinking; TE ACXL, transepithelial accelerated crosslinking.

Recently published IVCM studies in patients treated with ACXL^{15,16,41} at 30 mW/cm² demonstrated that anterior-mid stromal tissue presented a hyper-reflectivity of extracellular matrix surrounding multiple lacunar edematous areas associated with keratocyte loss (apoptosis, hence photonecrosis) as previously described after conventional CXL (Figures 5A and B). This was evident until the 3rd postoperative month (Figure 5C), gradually disappearing thereafter. Keratocyte repopulation began 1 month after treatment, increasing at the 3rd month and being complete at the 6th month (Figure 5D). An uneven demarcation line may be determined after pulsed light ACXL at a depth of 250 µm (measured from epithelial surface) on IVCM (Figure 6A), as confirmed by spectral domain corneal OCT (Figure 6B).^{16,30}

TE-ACXL with high-fluence UV-A power (45 mW/cm²) induced acute actinic keratitis with diffuse punctate epitheliopathy, which recovered following 3-4 days of soft contact lens bandage and sodium hyaluronate lubricants. Subepithelial nerves were damaged and partially disappeared after this high intensity UV-A power setting (similar to epithelium-off treatment), and corneal edema assumed a more diffuse rather than lacunar confocal appearance. A limited and uneven apoptotic effect was detectable after TE-ACXL in the anterior stroma at a mean depth of 80 µm (range 50-100 µm [(Figure 7A)]. Spectral domain corneal OCT scans confirmed an inhomogeneous reflectivity change concentrated under the Bowman's lamina without demarcation line evidence (Figure 7B).⁴¹

B. Limbus and Epithelium

IVCM analysis of limbal structures (Vogt's palisades) of the cornea after conventional CXL shows no evidence of pathological micromorphological changes in limbal stem cells. This is clinically confirmed by the fact that epithelium regenerates quickly (3 days on average), including the integrity of Bowman's lamina and absence of persistent epithelial deficit or delayed healing.^{23,24,26,36,58}

In CXL and ACXL, the central 9 mm of the epithelium are removed before the UV-A irradiation, and the irradiation field does not include the limbal epithelium. Because the central epithelium is removed, an intact limbal epithelium is of utmost importance, as the basal cells at the

base of the limbal epithelium are essential for the epithelial wound healing process and for preventing persistent epithelial defects and ulceration. As the basal limbal epithelial cells divide, they migrate from germinal epithelium of Vogt's palisades (Figures 8A-C) toward the center in a centripetal migration pattern and, later, to the surface, forming "wing cells" in the middle layers of the epithelium before they finally slough off at the outer surface. This dynamic process replaces the surface cell layers on a daily basis.

The incidental irradiation of the limbus during CXL should be carefully avoided to prevent an irreparable selective or generalized limbal deficit. The epithelium should be left in place on the limbus beyond a diameter of 9 mm, covering the cornea completely as far as the limbus. Defocus and/or tilting of the UV-A cross beams on the limbus should be avoided, while controlling the procedure in real time. Incidental irradiation of the limbal or conjunctival epithelium using UV-A with or without the photosensitizer riboflavin plus dextran with the standard irradiance of 3 mW/cm² for 30 minutes (as done in CXL) does not induce significant cellular conjunctival or corneal epithelial damage, as assessed by histological, immune-histological, and TUNEL techniques in the early phase after the irradiation. Therefore, accidental irradiation of the limbal epithelium during CXL does not seem to pose a threat for the induction of degenerative or neoplastic changes. A number of enzymatic and nonenzymatic antioxidant defense mechanisms and protection are present in the cornea to minimize and counteract oxidative damage induced by UVA, maintaining a cellular redox balance.^{26,58}

IVCM showed that after CXL and ACXL, basal corneal epithelium regenerates quickly (3-4 days) under a therapeutic soft contact lens bandage. One month after CXL, epithelium is generally thin (10-20 µm), and after 3 months the thickness increases to 30-40 µm on average, slightly less than the normal value of 55 µm. The normal thickness of epithelium, resembling preoperative pachymetry data, was detected between the 3rd and 6th months after the cross-linking procedure. IVCM of epithelium^{26,37} after conventional CXL at the first postoperative month showed large irregular cell borders with hyper-reflective spots (Figure 8D). IVCM revealed a

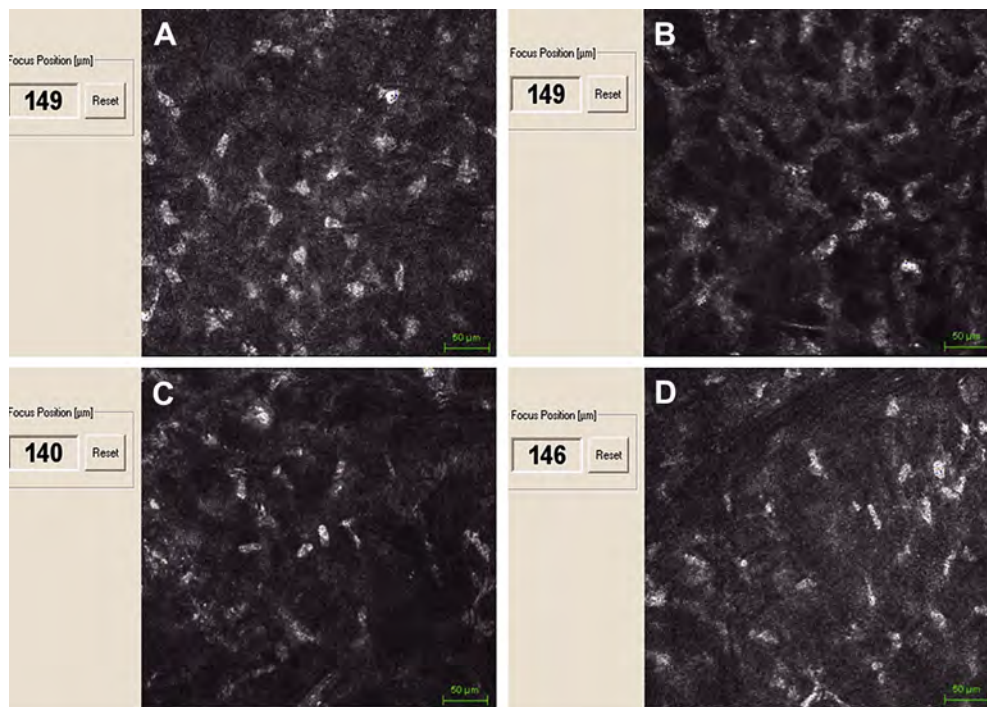


Figure 5. IVCM findings with ACXL. A: Preoperative scan. B: IVCM in the first postoperative month demonstrates multiple lacunar edematous areas associated with keratocyte loss in the anterior-mid stromal tissue. C: This aspect was evident until the 3rd postoperative month, with progressive edema reduction and increased number of keratocytes. D: Keratocyte repopulation is complete at the 6th postoperative month.

time-dependent postoperative stratification of basal epithelium, smoothing corneal surface irregularities during its progressive stratification, improving corneal optical properties, especially after the 3rd postoperative month (Figure 8C), with optimized mosaic quality at the 6th postoperative month (Figure 8F).^{23,24,26}

IVCM after TE-CXL at the first postoperative month (Figure 8G) showed diffuse necrotic areas devoid of epithelial cells, cytoplasmic rarefactions with increased intracellular reflectivity, and hyper-reflecting spots (apoptotic bodies). Three months after treatment, the intracellular reflectivity diminished, gradually returning to

preoperative status with a slow recovery of cell mosaic pattern and borders (Figure 8E). Six months after treatment, the epithelium was morphologically similar to that present before treatment, with a well-defined cell mosaic pattern.³⁶

C. Nerves

IVCM analysis after conventional CXL and ACXL showed features identical with the immediate loss of subepithelial plexus (SEP) nerves (Figure 9A). Regeneration of SEP fibers occurred with rapid growth from the surrounding nonirradiated area between the 2nd and 3rd postoperative

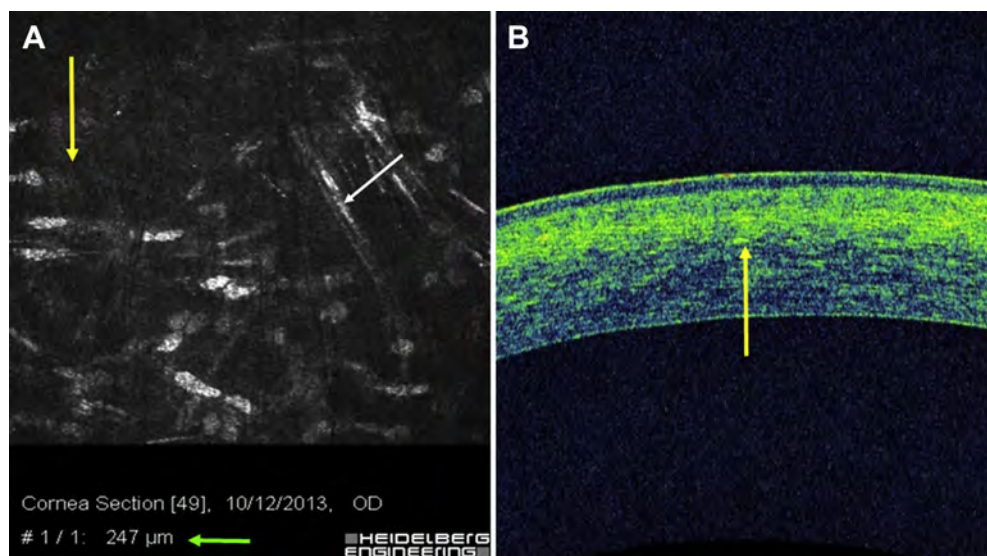


Figure 6. Demarcation may be determined after pulsed light ACXL at a depth of 220 microns on average (200-250 µm) at IVCM (A), as confirmed by spectral domain corneal OCT (B).

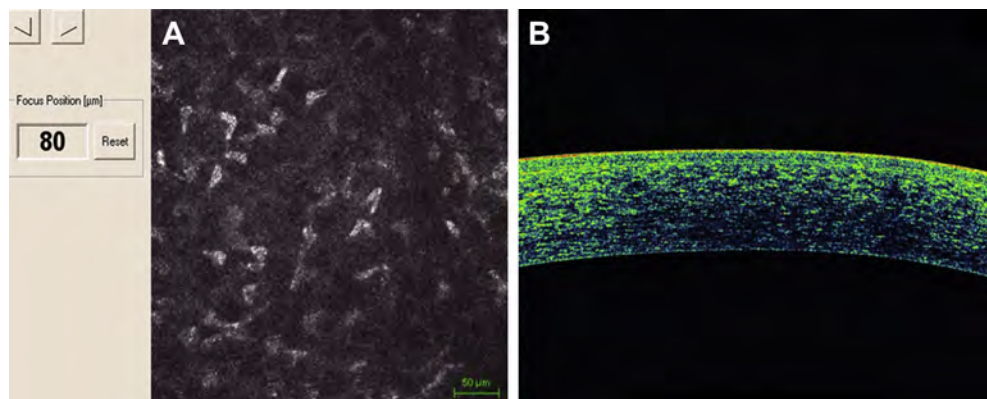


Figure 7. IVCM in high-fluence ACXL at 45 mW/cm^2 . Limited and uneven apoptotic effect was detectable after epithelium-on high-fluence ACXL in the anterior stroma at a mean depth of $80 \mu\text{m}$ (range $50\text{--}100 \mu\text{m}$; image A) confirmed by spectral domain corneal OCT scan that documented an inhomogeneous reflectivity change concentrated under the Bowman's lamina without demarcation line evidence (B).

months (Figure 9B). Regeneration of nerve fibers was almost complete 6 months after the operation, with fully restored corneal sensitivity (Figure 9C).

After 6 months, IVCM showed disconnected neural fibers under the Bowman's lamina (Figure 9B). The number of fibers increased progressively, and interconnections resembled the preoperative SEP structure 12 months after CXL and ACXL (Figure 9C).^{24,26-28,36}

The nerve fiber regeneration process on IVCM was initially characterized by the presence of native subepithelial nerve flocks simulating Langerhans cells in a "pseudodendritic pattern regeneration" (Figure 9B, white arrows). Langerhans cells were not present in preoperative scans nor in the first-month IVCM examinations, but were detectable between the 2nd and 3rd months. Although the possibility of transient postoperative inflammation cannot be excluded,⁵⁹ this repeatable observation indicates an initial re-innervation process characterized by sprouting nerve fibers. In our experience, inflammatory cells were sometimes discovered on IVCM analysis after removal of therapeutic contact lenses in patients with clinically evident red eye.

TE-ACXL with high-intensity UV-A power at 45 mW/cm^2 had the same pattern of nerve loss as conventional CXL and ACXL. We recorded SEP nerve loss in the first postoperative month (Figure 9D), followed by gradual nerve regeneration with disconnected fibers until the 6th postoperative month (Figure 9E), followed by interconnected fibers thereafter (Figure 9F). Changes in corneal transparency and neurotrophism related to kerato-neuro-dystrophic denervation mechanisms were never found after conventional CXL and ACXL.^{24,41}

IVCM analysis performed after TE-CXL at 3 mW/cm^2 showed that SEP and anterior-mid stromal nerves did not disappear. Nerve fibers were detectable by confocal analysis after removal of the therapeutic contact lens from the first postoperative month (Figure 9G). Similarly, SEP and stromal nerves were present in subsequent follow-up scans (Figures 9H and I), showing the typical increased reflectivity of nerves in keratoconic eyes, and a granular or "string-of-pearls" appearance with irregular paths and branch anomalies.^{29,34,36}

D. Endothelium

IVCM analysis after conventional CXL at 1-year (Figure 10A), 3-year (Figure 10B), and 5-year (Figure 10C) follow-up, and after ACXL at 6-month (Figure 10D), 12-month (Figure 10E) and 24-month (Figure 10F), follow-up confirmed the safety of both treatments, without morphological changes (unaltered hexagonality) or functional alterations (unchanged pachymetry values) of the corneal endothelium. Endothelial cell count was recorded with the I Konan, Non Con Robo specular microscope (Konan Medical Inc., Hyogo, Japan) and an average endothelial cell reduction of 2% per year was observed after treatment.^{15,16,24-26,29,36}

The long-term results of the Siena Eye Cross Study demonstrated a preoperative mean endothelial cell density of 2451 cells/mm^2 (range 2092 to 3016 cells/mm^2) with a statistically insignificant reduction in endothelial cell count with respect to a physiologic reduction, namely a mean of 2% per year in a maximum follow-up of 60 months.⁵

In an analysis of ACXL micromorphology, we found a preoperative mean endothelial cell density of 2510 cells/mm^2 (range 2082 to 3026 cells/mm^2) in a maximum follow-up of 24 months, without morphological differences between high irradiance continuous and pulsed light treatments. Human IVCM studies confirmed that the selective cytotoxic effects of CXL treatment are concentrated in the anterior cornea due to high absorption of UV-A by riboflavin, which prevents the radiation from reaching deeper levels and thus protects the endothelium, lens, and retina.^{15,16,36,40,44}

Although it is reasonable to consider that such endothelial damage could be below the resolution limit of confocal microscopy, this was not recorded in our patients nor reported in the literature, except with conventional CXL in thin corneas.⁶⁰

IV. DISCUSSION

Riboflavin UV-A CXL represents the only "pathogenic approach" available for progressive keratoconus and post-LASIK corneal ectasia that can delay or block progression, reducing the need for donor keratoplasty.^{5,7,8,17,24,26,29,61-65}

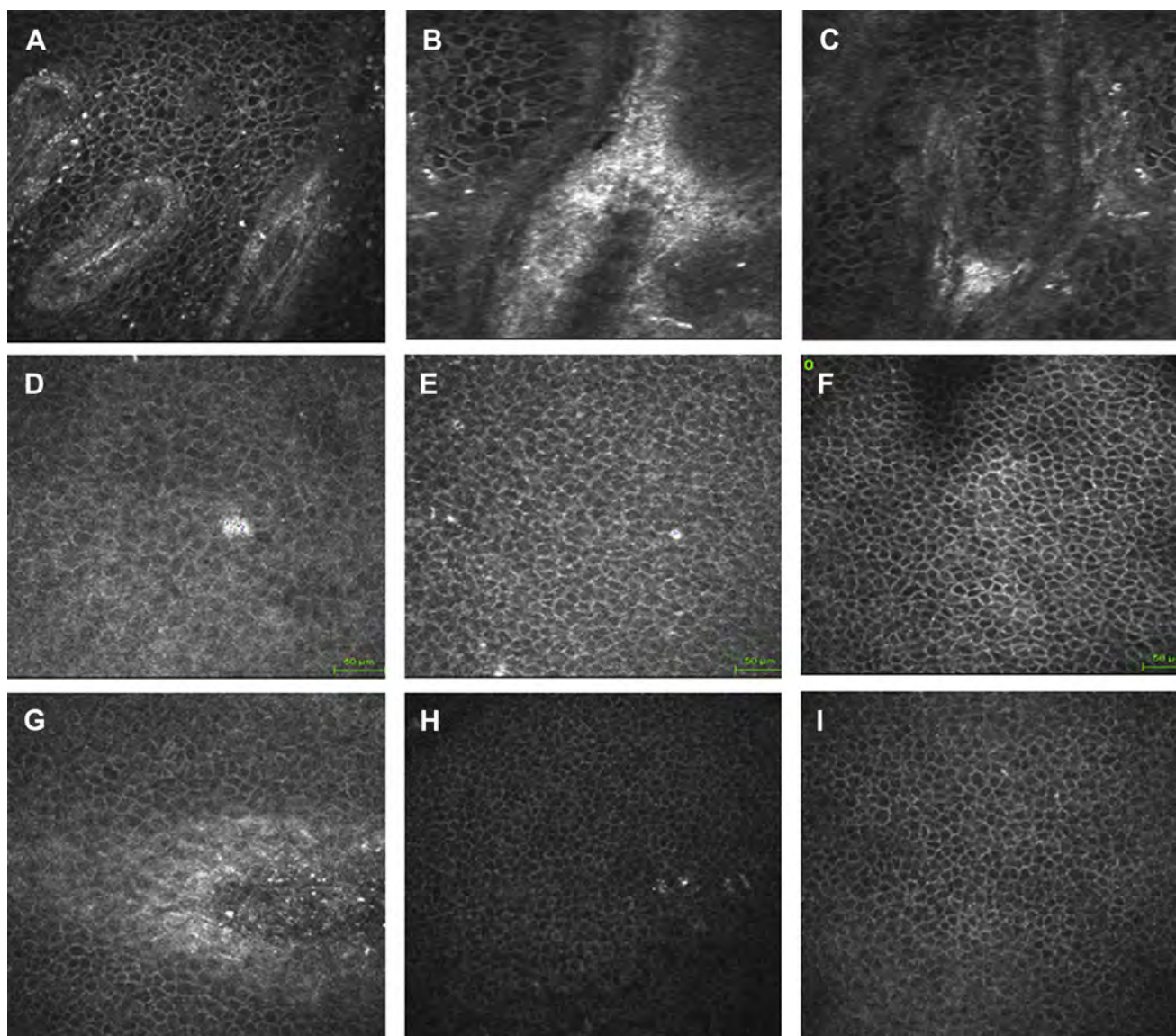


Figure 8. IVCM analysis of limbal structures (Vogt's palisades) of the cornea after conventional CXL did not show pathological micromorphological changes in limbal stem cell line. Basal limbal epithelial cells (bright particles spreading from coronal germinal epithelium of limbal Vogt palisades) divide and migrate (A-C) toward the center in a centripetal migration pattern and later to the surface. IVCM of epithelium after conventional CXL at first postoperative month (D) showed irregular cell borders with hyper-reflective spots. Postoperative stratification of basal epithelium improving corneal optical properties at 3rd postoperative month (E) and optimized mosaic quality at 6th postoperative month (F). IVCM after TE-CXL showed immediate diffuse necrotic areas devoid of epithelial cells and hyper-reflecting spots (apoptotic bodies; image G). Three months after treatment, mosaic pattern and cell borders are visible (H). Between the 3rd and 6th months, the epithelium resembled preoperative conditions (I).

The summary of IVCM study findings after conventional CXL^{16,23,24,26-29,36,47,50,66,67} shown in Table 3 demonstrates general scientific agreement with regard to the spatial and temporal definition of cellular repair processes. Conventional riboflavin-UVA-induced corneal CXL has proven to be a safe and effective therapy in slowing down the evolution of progressive keratoconus and secondary ectasia in the medium-to-long term in the absence of severe complications.^{10,14,17,34,68} One of the strongest pieces of IVCM microstructural evidence in favor of conventional CXL was the depth of the demarcation line that was homogeneously found at a depth of 300 μm (2/3 of

the entire stroma) with high repeatability in all studies. This morphological feature was linked with the best biomechanical and clinical outcomes. Current evidence on the safety and efficacy of conventional CXL for keratoconus and keratectasia was considered adequate in quality and quantity, leading to clinical approval by the National Institute for Health and Clinical Excellence (NICE) in the United Kingdom.⁶⁹

Although conventional CXL temporarily induces anterior-mid stromal keratocyte apoptosis and the disappearance of the SEP nerve fibers, qualitative IVCM observations and quantitative data unequivocally showed a

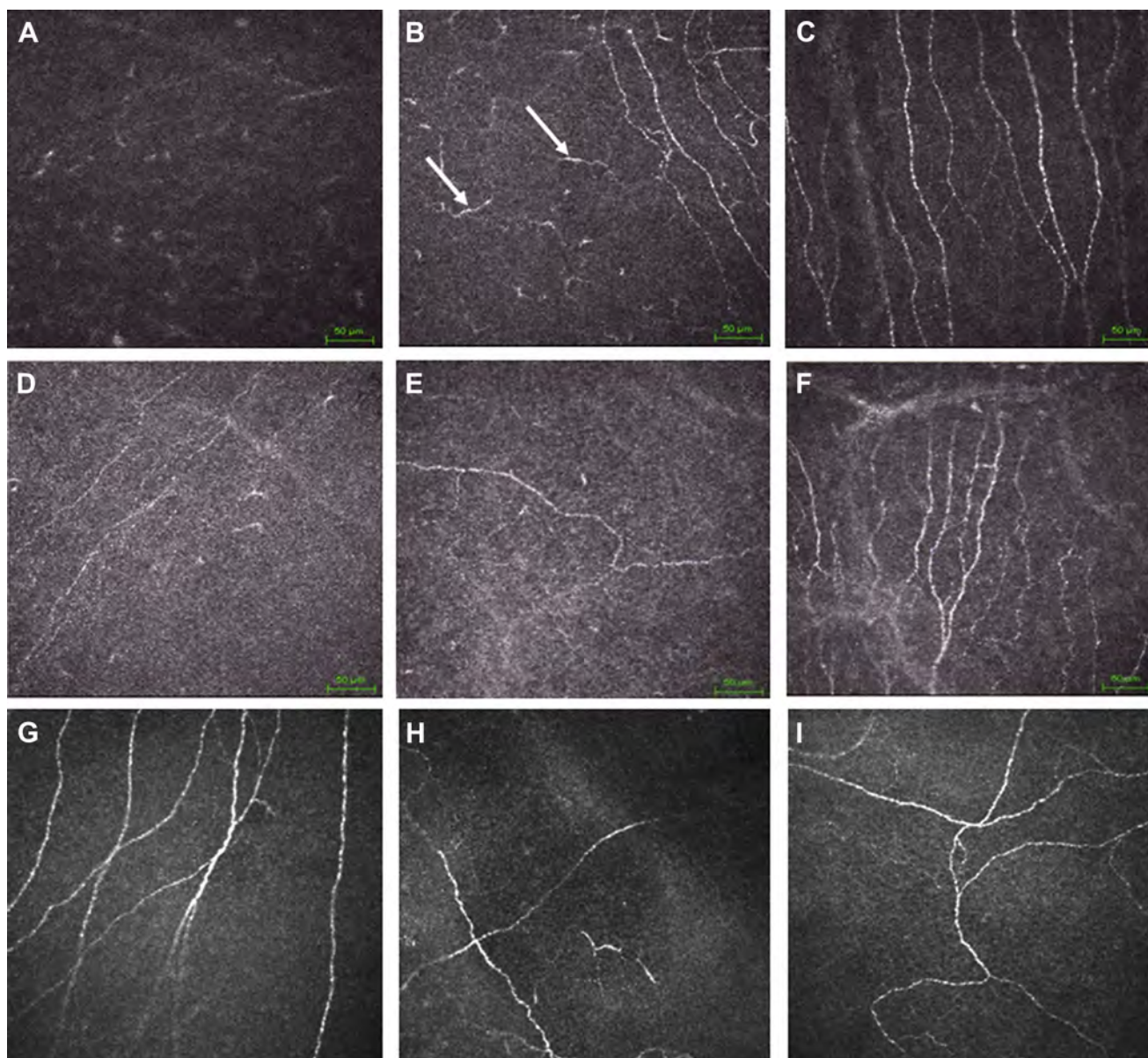


Figure 9. IVCM after conventional CXL and ACXL showed identical features with immediate disappearance of subepithelial plexus (SEP) nerve fibers (A). Regeneration started rapidly and subepithelial nerve flocculation simulated the presence of dendritic cells: “pseudo-dendritic nerves regeneration” (B, white arrows). Regeneration of nerve fibers was almost complete 6 months after the operation, with fully restored corneal sensitivity (C). IVCM after TE-ACXL with high intensity UV-A power (45 mW/cm^2) determined a nerve loss similar to that with conventional CXL (D) followed by gradual nerve regeneration of disconnected fibers (E) followed by interconnected fibers after the 6th month (F). IVCM after TE-CXL showed that SEP nerves did not disappear (G). Similarly, SEP nerves were present in subsequent follow-up scans (H and I).

return to baseline values at 12 months postoperatively (Table 3). Further, nerve fibers regenerate rapidly in 12 months, finally having no neurodystrophic effects and achieving normal corneal sensitivity and lacrimal reflex.⁷⁰⁻⁷³ Beyond the presence of activated keratocyte nuclei and increased density of the extracellular matrix initially surrounding lacunar edema, inflammatory cells were not detected in corneal stroma after conventional CXL.

IVCM analysis in TE-CXL showed transitory alteration of corneal epithelial cells. The toxic effect on the epithelium is naturally related to photonecrosis and UV-A-induced apoptosis affecting epithelial cell turnover in the first

1-3 months after treatment. Epithelial cell turnover is further delayed and altered by the toxic effect of anesthetics, surfactants, tension-enhancers, and preservatives used in transepithelial riboflavin solutions, often inducing a diffuse punctate epitheliopathy that requires a postoperative therapeutic soft contact lens bandage. A limited, superficial, and unevenly distributed apoptotic effect is detectable after TE-CXL, with no endothelial damage observed during the follow-up.

On the other hand, after TE-CXL, patients have no glare disability in the first 1-2 postoperative months, as occurs with epithelium-off procedures, and there is no loss of

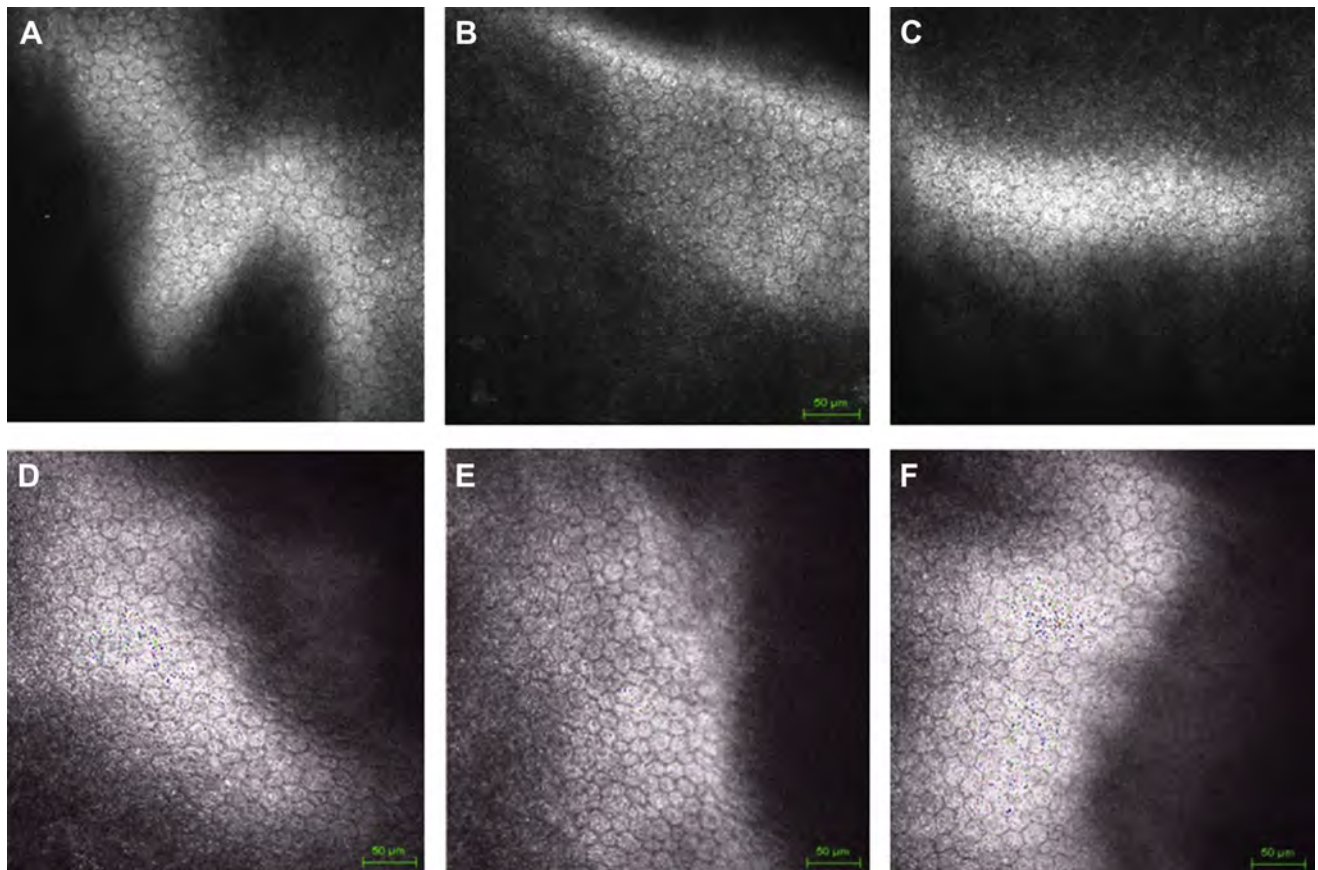


Figure 10. IVCM analysis of current state-of-the-art conventional CXL at 1-year (A), 3-year (B) and 5-year (C) follow-up and ACXL after 6-month (D), 1-year (E), and 18-month (F) follow-up confirmed the safety of the treatments, without morphological or functional alterations of the corneal endothelium. The endothelial cell reduction observed after treatment was 2% per year on average.

SEP^{36,46} nerve fibers, such as that which occurred after transepithelial high-fluence ACXL at 45 mW/cm², likely due to a very high UV-A power setting.⁴¹

Qualitative and quantitative IVCM studies (Table 3) homogeneously revealed reduced penetration of the photo-oxidative cell damage, which explains the limitation of the biomechanical effect recorded after TE-CXL.⁷⁴ The limited effect reduces the possibility of stabilizing keratoconus in the long-term, as demonstrated in pediatric patients after the 24-month follow-up.⁴⁰ Moreover the classical demarcation lines observed after conventional CXL were generally not detectable after TE-CXL treatments, as confirmed by IVCM and spectral domain corneal OCT.^{15-18,29,75}

According to IVCM findings, biomechanical studies, and clinical evidence, TE-CXL as classically conceived with 3mW/cm² UV-A power associated with “enhanced” riboflavin solutions can be considered limited and inferior to other methods. “Supporters” of TE-CXL are directing their efforts to iontophoretic electric-assisted delivery of riboflavin into the corneal stroma via an “apparently” intact epithelium combined with ACXL at 9 mW/cm² of UV-A power. Two factors should be kept in mind: 1) after iontophoresis, the intrastromal concentration of riboflavin is about 50% of the concentration achieved by passive

diffusion after epithelium removal⁷⁶; and 2) the demarcation line is not visible after iontophoresis CXL and cell viability is variable, irregularly distributed in the anterior stroma up to 200 µm measured from the epithelial surface,⁷⁷ meaning that crosslinking penetration reaches the first 150 µm of the stroma and may be insufficient to obtain long-term stabilization of ectasia. This may be the same limit of ACXL with continuous light at 30mW/cm², which demonstrated the same penetration; however, with ACXL by removing the epithelium, a photo-oxidative effect and demarcation line are well detectable on IVCM and corneal OCT.⁷⁸

Qualitative and quantitative IVCM studies^{16,29,50,67} with ACXL at 30 mW/cm² (Table 4) show preliminary scientific agreement in the measurement of treatment penetration (keratocyte photo-oxidative damage is under 200 µm of depth). Postoperative edema and density of extracellular matrix were higher than in conventional CXL in the first 3 postoperative months; however, nerves and cell density returned to baseline values between the 6th and 12th postoperative months. This does not seem to be the case when crosslinking is combined with photo-ablation of the cornea (CXL-plus).⁶³ In this case, the disappearance of Bowman’s lamina due to excimer laser photo-ablation may

Table 3. Summary of in vivo confocal microscopy findings after conventional CXL

Author	Country	Treatment	Design	N. of eyes	Follow-up (months)	Epithelial healing (days)	Nerves regeneration (months)	Keratocytes repopulation (months)	Endothelium
Mazzotta et al. 2006	Italy	CXL	qualitative	10	6	5	6	n.a.	Unaltered
Mazzotta et al. 2007	Italy	CXL	qualitative	10	6	4	6	6	Unaltered
Mazzotta et al. 2008	Italy	CXL	qualitative	44	36	4	12	6	Unaltered
Kymionis et al. 2009	Greece	CXL	qualitative	10	6	4	6	6	Unaltered
Croxatto et al. 2010	Argentina	CXL	qualitative	18	36	4	6	6	Unaltered
Knappe et al. 2011	Germany	CXL	qualitative	8	12	14	12	6	Unaltered
Caporossi et al. 2012	Italy	TE-CXL	qualitative	10	6	4	no nerve loss	unchanged	Unaltered
Toboul et al. 2012	France	TE-CXL	qualitative	8	6	3	no nerve loss	unchanged	Unaltered
Jordan et al. 2014	N. Zealand	CXL	quantitative	38	12	n.a.	12 (to baseline values)	12 (to baseline values)	Unaltered
Sharma et al. 2015	India	CXL	qualitative	23	6	7	6	6	Unaltered

n. a., not available; CXL, conventional epithelium-off CXL; TE-CXL, transepithelial CXL.

Table 4. Summary of in vivo confocal microscopy findings after accelerated CXL (ACXL)

Author	Country	Treatment	Design	N. of eyes	Follow-up (months)	Epithelial healing (days)	Nerves regeneration (months)	Keratocytes repopulation (months)	Endothelium
Toboul et al. 2012	France	ACXL	qualitative	8	6	3	n.a.	6	Unaltered
Mazzotta et al. 2014	Italy	ACXL	qualitative	20	6	4	6	6	Unaltered
Bouheraoua et al. 2014	France	ACXL	quantitative	15	6	n.a.	6 (partial)	6 (partial)	Unaltered

n. a., not available; ACXL, Accelerated CXL.

lead to a greater UV-A toxicity due to the loss of Bowman's layer antioxidant role. However, in our experience, after CXL-plus laser photo-ablation, the keratocyte repopulation is delayed compared to conventional CXL alone, returning to baseline values after 18-24 months instead of 12 months. No endothelial damage was observed in terms of morphology and cell count after ACXL.^{15-18,29,75}

IVCM is useful not only for assessing the safety and efficacy of conventional, transepithelial and accelerated cross-linking but also for elucidating the mechanisms by which crosslinking works. There is a reasonable correlation between confocal aspects and tomographic data that helps to explain the functional and biomechanical effect of cross-linking. The so-called "push-up" effect of the corneal apex can be explained with the increase in topographic indices of symmetry detectable by serial differential topography. Central "flattening" observed in differential altimetry mapping after treatment leads to variable postoperative visual improvements. Conventional CXL induces a "variable remodelling and compaction" of stromal collagen, packing stromal lamellae, retracting microfibrils, and changing the refraction index of the cornea.^{17,37} We know that in vivo riboflavin-UV-A-induced oxidative damage (apoptotic effect and cell viability) depends on the energy, riboflavin concentration, and mode of exposure. Thus, the exposure time together with riboflavin concentration becomes very important in CXL treatment (interactions between UV-A photons, riboflavin and collagen).^{42,43,45} To date, we still do not know the exact optimal interactions between UV-A energy, riboflavin concentration, and exposure time needed to obtain the maximum crosslinking effect ensuring long-lasting (possibly life-long) stabilization of keratoconus and the best functional outcomes, even though recent scientific progress concerning IVCM and in vivo Young's modulus evaluation are leading to a more controlled and adjustable modification of CXL treatment.

According to IVCM micromorphological studies, the conventional CXL procedure with riboflavin 0.1%, UV-A at 3mW/cm², 5.4 J/cm² for 30 minutes, remains a benchmark of the conservative treatment of early-stage progressive keratoconus. On the other hand, the Bunsen-Roscoe's law of reciprocity that was established for photochemical reactions paved the way for ACXL protocols, showing it was safe for endothelium and posterior ocular structures. ACXL penetration reaches the anterior part of the stroma, stiffening the cornea between 150 and 200 µm, with relative differences between the different protocols.^{17,18,26,30}

We believe that IVCM will promote further advances in CXL for the treatment of progressive corneal ectasia and will provide more insights into corneal changes. This will contribute to customization of CXL alone or in combination with other techniques for refractive empowerment (CXL-plus).⁷⁹ According to biomechanical studies, CXL should cover at least 200 µm of corneal stroma⁸⁰ and UV-A power and exposure time should be targeted to achieve this depth. This is possible after epithelium removal

and calibrating the UV-A power between 9 and 15mW/cm² at E dose of 5.4 J/cm². This data emerged from the laboratory study performed by Krueger, Herekar, and Spoerl,⁸¹ demonstrating that effective crosslinking requires the presence of oxygen⁸² in addition to a sufficient penetration of riboflavin and UV-A exposure. The study demonstrated that high-irradiance CXL with UV-A exposures of 9mW/cm² and 15mW/cm² was equally efficacious (using an equivalent total energy exposure of 5.4 J/cm²), indicating efficacy in stiffening corneal collagen that is comparable to that achieved with standard irradiance of 3mW/cm², but with the advantage of considerably less exposure time.

In conclusion, we can affirm that the rapidity of high-irradiance crosslinking offers great advantage in clinical applications in which 30 minutes is too long for most clinicians and their patients. IVCM studies confirm that CXL is still undergoing development and protocol adjustments. Careful evaluation of efficacy and safety of these modifications should be investigated by various methods and by multiple study groups.

ACKNOWLEDGEMENT

The authors thank Mrs. Jennifer Anne Berkley for editing the article.

REFERENCES

- Rabinowitz YS. Keratoconus. *Surv Ophthalmol* 1998;42:297-319
- Rabinowitz YS. The genetics of keratoconus. *Ophthalmol Clin N Am* 2003;16:607-20
- Wollensak G, Spoerl E, Seiler T. Riboflavin/ultraviolet-a-induced collagen crosslinking for the treatment of keratoconus. *Am J Ophthalmol* 2003;135:620-7
- Caporossi A, Baiocchi S, Mazzotta C, et al. Parasurgical therapy for keratoconus by riboflavin-ultraviolet type A rays induced cross-linking of corneal collagen: preliminary refractive results in an Italian study. *J Cataract Refract Surg* 2006;32:837-45. <http://dx.doi.org/10.1016/j.jcrs.2006.01.091>
- Caporossi A, Mazzotta C, Baiocchi S, Caporossi T. Long-term results of riboflavin ultraviolet A corneal collagen cross-linking for keratoconus in Italy: the Siena eye cross study. *Am J Ophthalmol* 2010;149:585-93. <http://dx.doi.org/10.1016/j.ajo.2009.10.021>
- Caporossi A, Mazzotta C, Baiocchi S, et al. Age-related long-term functional results after Riboflavin UV A corneal cross-linking. *J Ophthalmol* 2011;2011:e608041. <http://dx.doi.org/10.1155/2011/608041>
- Hafezi F, Kanellopoulos J, Wiltfang R, Seiler T. Corneal collagen cross-linking with riboflavin and ultraviolet A to treat induced keratectasia after laser in situ keratomileusis. *J Cataract Refract Surg* 2007;33:2035-40. <http://dx.doi.org/10.1016/j.jcrs.2007.07.028>
- Richoz O, Mavranakas N, Pajic B, Hafezi F. Corneal collagen cross-linking for ectasia after LASIK and photorefractive keratectomy: long-term results. *Ophthalmology* 2013;120:1354-9. <http://dx.doi.org/10.1016/j.ophtha.2012.12.027>
- Spoerl E, Seiler T. Techniques for stiffening the cornea. *J Refract Surg* 1999;15:711-3
- Da Paz AC, Bersanetti PA, Salomão MQ, et al. Theoretical basis, laboratory evidence, and clinical research of chemical surgery of the cornea: cross-linking. *J Ophthalmol* 2014;2014:e890823. <http://dx.doi.org/10.1155/2014/890823>
- Raiskup F, Spoerl E. Corneal crosslinking with riboflavin and ultraviolet A. I. Principles. *Ocul Surf* 2013;11:65-74. <http://dx.doi.org/10.1016/j.jtos.2013.01.002>
- Raiskup-Wolf F, Hoyer A, Spoerl E, Pillunat LE. Collagen crosslinking with riboflavin and ultraviolet-A light in keratoconus: long-term results. *J Cataract Refract Surg* 2008;34:796-801. <http://dx.doi.org/10.1016/j.jcrs.2007.12.039>
- Raiskup F, Spoerl E. Corneal crosslinking with riboflavin and ultraviolet A. Part II. Clinical indications and results. *Ocul Surf* 2013;11:93-108. <http://dx.doi.org/10.1016/j.jtos.2013.01.003>
- Wittig-Silva C, Chan E, Islam FMA, et al. A randomized, controlled trial of corneal collagen cross-linking in progressive keratoconus: three-year results. *Ophthalmology* 2014;121(4):812-21. <http://dx.doi.org/10.1016/j.ophtha.2013.10.028>
- Mazzotta C, Traversi C, Paradiso AL, et al. Pulsed light accelerated crosslinking versus continuous light accelerated crosslinking: one-year results. *J Ophthalmol* 2014;2014:e604731. <http://dx.doi.org/10.1155/2014/604731>
- Mazzotta C, Traversi C, Caragiuli S, Rechichi M. Pulsed vs continuous light accelerated corneal collagen crosslinking: in vivo qualitative investigation by confocal microscopy and corneal OCT. *Eye (Lond)* 2014;28:1179-83. <http://dx.doi.org/10.1038/eye.2014.163>
- Mazzotta C, Balestrazzi A, Traversi C, et al. In vivo confocal microscopy report after Lasik with sequential accelerated corneal collagen cross-linking treatment. *Case Rep Ophthalmol* 2014;5:125-31. <http://dx.doi.org/10.1159/000362327>
- Mrochen M. Current status of accelerated corneal cross-linking. *Indian J Ophthalmol* 2013;61:428-9. <http://dx.doi.org/10.4103/0301-4738.116075>
- Kanellopoulos AJ, Asimellis G. Epithelial remodeling after partial topography-guided normalization and high-fluence short-duration crosslinking (Athens protocol): results up to 1 year. *J Cataract Refract Surg* 2014;40:1597-602. <http://dx.doi.org/10.1016/j.jcrs.2014.02.036>
- Kanellopoulos AJ, Asimellis G. Keratoconus management: long-term stability of topography-guided normalization combined with high-fluence CXL stabilization (the Athens Protocol). *J Refract Surg* 2014;30:88-93. <http://dx.doi.org/10.3928/1081597X-20140120-03>
- Mita M, Waring GO, Tomita M. High-irradiance accelerated collagen crosslinking for the treatment of keratoconus: six-month results. *J Cataract Refract Surg* 2014;40:1032-40. <http://dx.doi.org/10.1016/j.jcrs.2013.12.014>
- Wernli J, Schumacher S, Spoerl E, Mrochen M. The efficacy of corneal cross-linking shows a sudden decrease with very high intensity UV light and short treatment time. *Invest Ophthalmol Vis Sci* 2013;54:1176-80. <http://dx.doi.org/10.1167/iiov.12-11409>
- Mazzotta C, Traversi C, Baiocchi S, et al. Conservative treatment of keratoconus by riboflavin-UVA-induced cross-linking of corneal collagen: qualitative investigation. *Eur J Ophthalmol* 2006;16(4):530-5
- Mazzotta C, Balestrazzi A, Traversi C, et al. Treatment of progressive keratoconus by riboflavin-UVA-induced cross-linking of corneal collagen: ultrastructural analysis by Heidelberg Retinal Tomograph II in vivo confocal microscopy in humans. *Cornea* 2007;26:390-7. <http://dx.doi.org/10.1097/ICO.0b013e318030df5a>
- Mazzotta C, Balestrazzi A, Baiocchi S, et al. Stromal haze after combined riboflavin-UVA corneal collagen cross-linking in keratoconus: in vivo confocal microscopic evaluation. *Clin Experiment Ophthalmol* 2007;35:580-2. <http://dx.doi.org/10.1111/j.1442-9071.2007.01536.x>
- Mazzotta C, Traversi C, Baiocchi S, et al. Corneal healing after riboflavin ultraviolet-A collagen cross-linking determined by confocal laser scanning microscopy in vivo: early and late modifications. *Am J Ophthalmol* 2008;146:527-33. <http://dx.doi.org/10.1016/j.ajo.2008.05.042>
- Kymionis GD, Diakonis VF, Kalyvianaki M, et al. One-year follow-up of corneal confocal microscopy after corneal cross-linking in patients with post laser in situ keratomileusis ectasia and keratoconus. *Am J*

- Ophthalmol* 2009;147:774-8. 778.e1. <http://dx.doi.org/10.1016/j.ajo.2008.11.017>
28. Croxatto JO, Tytun AE, Argento CJ. Sequential in vivo confocal microscopy study of corneal wound healing after cross-linking in patients with keratoconus. *J Refract Surg* 2010;26:638-45. <http://dx.doi.org/10.3928/1081597X-20091111-01>
 29. Touboul D, Efron N, Smadja D, et al. Corneal confocal microscopy following conventional, transepithelial, and accelerated corneal collagen cross-linking procedures for keratoconus. *J Refract Surg* 2012;28:769-76. <http://dx.doi.org/10.3928/1081597X-20121016-01>
 30. Kymionis GD, Grentzelos MA, Plaka AD, et al. Correlation of the corneal collagen cross-linking demarcation line using confocal microscopy and anterior segment optical coherence tomography in keratoconic patients. *Am J Ophthalmol* 2014;157:110-115.e1. <http://dx.doi.org/10.1016/j.ajo.2013.09.010>
 31. Minsky M. Memoir on inventing the confocal scanning microscope. *Scanning* 1988;10:128-38. <http://dx.doi.org/10.1002/sca.4950100403>
 32. Patel DV, McGhee CNJ. Contemporary in vivo confocal microscopy of the living human cornea using white light and laser scanning techniques: a major review. *Clin Experiment Ophthalmol* 2007;35:71-88. <http://dx.doi.org/10.1111/j.1442-9071.2007.01423.x>
 33. Patel DV, McGhee CN. Quantitative analysis of in vivo confocal microscopy images: A review. *Surv Ophthalmol* 2013;58:466-75. <http://dx.doi.org/10.1016/j.survophthal.2012.12.003>
 34. Efron N, Hollingsworth JG. New perspectives on keratoconus as revealed by corneal confocal microscopy. *Clin Exp Optom J Aust Optom Assoc* 2008;91:34-55. <http://dx.doi.org/10.1111/j.1444-0938.2007.00195.x>
 35. Mazzotta C, Baiocchi S, Denaro R, et al. Corneal collagen cross-linking to stop corneal ectasia exacerbated by radial keratotomy. *Cornea* 2011;30:225-8. <http://dx.doi.org/10.1097/ICO.0b013e3181e16de5>
 36. Caporossi A, Mazzotta C, Baiocchi S, et al. Transepithelial corneal collagen crosslinking for keratoconus: qualitative investigation by in vivo HRT II confocal analysis. *Eur J Ophthalmol* 2012;22(Suppl 7):S81-8. <http://dx.doi.org/10.5301/ejo.5000125>
 37. Mazzotta C, Caporossi T, Denaro R, et al. Morphological and functional correlations in riboflavin UV A corneal collagen cross-linking for keratoconus. *Acta Ophthalmol (Copenh)* 2012;90:259-65. <http://dx.doi.org/10.1111/j.1755-3768.2010.01890.x>
 38. Raiskup F, Hoyer A, Spoerl E. Permanent corneal haze after riboflavin-UVA-induced cross-linking in keratoconus. *J Refract Surg* 2009;25:S824-8. <http://dx.doi.org/10.3928/1081597X-20090813-12>
 39. Leccisotti A, Islam T. Transepithelial corneal collagen cross-linking in keratoconus. *J Refract Surg* 2010;26:942-8. <http://dx.doi.org/10.3928/1081597X-20100212-09>
 40. Caporossi A, Mazzotta C, Paradiso AL, et al. Transepithelial corneal collagen crosslinking for progressive keratoconus: 24-month clinical results. *J Cataract Refract Surg* 2013;39:1157-63. <http://dx.doi.org/10.1016/j.jcrs.2013.03.026>
 41. Mazzotta C, Paradiso AL, Baiocchi S, et al. Qualitative investigation of corneal changes after accelerated corneal collagen cross-linking (A-CXL) by in vivo confocal microscopy and corneal OCT. *J Clin Exp Ophthalmol* 2013;4:313. <http://dx.doi.org/10.4172/2155-9570.1000313>
 42. Wollensak G, Spoerl E, Reber F, Seiler T. Keratocyte cytotoxicity of riboflavin/UVA-treatment in vitro. *Eye (Lond)* 2004;18:718-22. <http://dx.doi.org/10.1038/sj.eye.6700751>
 43. Wollensak G, Spoerl E, Wilsch M, Seiler T. Keratocyte apoptosis after corneal collagen cross-linking using riboflavin/UVA treatment. *Cornea* 2004;23:43-9
 44. Wollensak G, Spoerl E, Wilsch M, Seiler T. Endothelial cell damage after riboflavin-ultraviolet-A treatment in the rabbit. *J Cataract Refract Surg* 2003;29:1786-90
 45. Wollensak G, Wilsch M, Spoerl E, Seiler T. Collagen fiber diameter in the rabbit cornea after collagen crosslinking by riboflavin/UVA. *Cornea* 2004;23:503-7
 46. Al-Aqaba M, Calienno R, Fares U, et al. The effect of standard and transepithelial ultraviolet collagen cross-linking on human corneal nerves: an ex vivo study. *Am J Ophthalmol* 2012;153:258-266.e2. <http://dx.doi.org/10.1016/j.ajo.2011.07.006>
 47. Jordan C, Patel DV, Abeysekera N, McGhee CNJ. In vivo confocal microscopy analyses of corneal microstructural changes in a prospective study of collagen cross-linking in keratoconus. *Ophthalmology* 2014;121:469-74. <http://dx.doi.org/10.1016/j.ophtha.2013.09.014>
 48. Gutiérrez R, Lopez I, Villa-Collar C, González-Méijome JM. Corneal transparency after cross-linking for keratoconus: 1-year follow-up. *J Refract Surg* 2012;28:781-6. <http://dx.doi.org/10.3928/1081597X-20121011-06>
 49. Greenstein SA, Fry KL, Bhatt J, Hersh PS. Natural history of corneal haze after collagen crosslinking for keratoconus and corneal ectasia: Scheimpflug and biomicroscopic analysis. *J Cataract Refract Surg* 2010;36:2105-14. <http://dx.doi.org/10.1016/j.jcrs.2010.06.067>
 50. Bouheraoua N, Jouve L, El Sanharawi M, et al. Optical coherence tomography and confocal microscopy following three different protocols of corneal collagen-crosslinking in keratoconus. *Invest Ophthalmol Vis Sci* 2014;55:7601-9. <http://dx.doi.org/10.1167/iovs.14-15662>
 51. Gokhale NS. Corneal endothelial damage after collagen cross-linking treatment. *Cornea* 2011;30:1495-8. <http://dx.doi.org/10.1097/ICO.0b013e31820687f7>
 52. Carr JD, Patel R, Hersh PS. Management of late corneal haze following photorefractive keratectomy. *J Refract Surg* 1995;11(3 Suppl):S309-13
 53. Koller T, Mrochen M, Seiler T. Complication and failure rates after corneal crosslinking. *J Cataract Refract Surg* 2009;35:1358-62. <http://dx.doi.org/10.1016/j.jcrs.2009.03.035>
 54. Lim LS, Beuerman R, Lim L, Tan DTH. Late-onset deep stromal scarring after riboflavin-UV-A corneal collagen cross-linking for mild keratoconus. *Arch Ophthalmol* 2011;129:360-2. <http://dx.doi.org/10.1001/archophthalmol.2011.23>
 55. Seiler TG, Schmidinger G, Fischinger I, et al. [Complications of corneal cross-linking]. *Ophthalmol Z Dtsch Ophthalmol Ges* 2013;110:639-44. <http://dx.doi.org/10.1007/s00347-012-2682-0>. German
 56. Cannon CJ, Marshall J, Patmore AL, et al. Persistent haze and disorganization of anterior stromal collagen appear unrelated following phototherapeutic keratectomy. *J Refract Surg* 2003;19:323-32
 57. Seiler T, Hafezi F. Corneal cross-linking-induced stromal demarcation line. *Cornea* 2006;25:1057-9. <http://dx.doi.org/10.1097/01.ico.0000225720.38748.58>
 58. Wollensak G, Mazzotta C, Kalinski T, Sel S. Limbal and conjunctival epithelium after corneal cross-linking using riboflavin and UVA. *Cornea* 2011;30:1448-54. <http://dx.doi.org/10.1097/ICO.0b013e3182199d7e>
 59. Zhivov A, Stave J, Vollmar B, Guthoff R. In vivo confocal microscopic evaluation of Langerhans cell density and distribution in the normal human corneal epithelium. *Graefes Arch Clin Exp Ophthalmol* 2005;243:1056-61. <http://dx.doi.org/10.1007/s00417-004-1075-8>
 60. Kymionis GD, Portaliou DM, Diakonis VF, et al. Corneal collagen cross-linking with riboflavin and ultraviolet-A irradiation in patients with thin corneas. *Am J Ophthalmol* 2012;153:24-8. <http://dx.doi.org/10.1016/j.ajo.2011.05.036>
 61. Kymionis GD, Grentzelos MA, Kankariya VP, Pallikaris IG. Combined transepithelial phototherapeutic keratectomy and corneal collagen crosslinking for ectatic disorders: Cretan protocol. *J Cataract Refract Surg* 2013;39:1939. <http://dx.doi.org/10.1016/j.jcrs.2013.10.003>
 62. O'Brart DPS. Corneal collagen cross-linking: A review. *J Optom* 2014;7:113-24. <http://dx.doi.org/10.1016/j.optom.2013.12.001>

63. Alessio G, L'Abbate M, Furino C, et al. Confocal microscopy analysis of corneal changes after photorefractive keratectomy plus cross-linking for keratoconus: 4-year follow-up. *Am J Ophthalmol* 2014;158:476-484.e1. <http://dx.doi.org/10.1016/j.ajo.2014.05.024>
64. Ku JYF, Niederer RL, Patel DV, et al. Laser scanning in vivo confocal analysis of keratocyte density in keratoconus. *Ophthalmology* 2008;115:845-50. <http://dx.doi.org/10.1016/j.ophtha.2007.04.067>
65. Dawson DG, Holley GP, Geroski DH, et al. Ex vivo confocal microscopy of human LASIK corneas with histologic and ultrastructural correlation. *Ophthalmology* 2005;112:634-44. <http://dx.doi.org/10.1016/j.ophtha.2004.10.040>
66. Knappe S, Stachs O, Zhivov A, et al. Results of confocal microscopy examinations after collagen cross-linking with riboflavin and UVA light in patients with progressive keratoconus. *Ophthalmologica* 2011;225:95-104. <http://dx.doi.org/10.1159/000319465>
67. Sharma N, Suri K, Sehra SV, et al. Collagen cross-linking in keratoconus in Asian eyes: visual, refractive and confocal microscopy outcomes in a prospective randomized controlled trial. *Int Ophthalmol* 2015. <http://dx.doi.org/10.1007/s10792-015-0054-x>
68. Dhawan S, Rao K, Natrajan S. Complications of corneal collagen cross-linking. *J Ophthalmol* 2011;2011:e869015. <http://dx.doi.org/10.1155/2011/869015>
69. Photochemical corneal collagen cross-linkage using riboflavin and ultraviolet A for keratoconus and keratectasia | Guidance and guidelines | NICE. <http://www.nice.org.uk/guidance/ipg466>. Accessed March 22, 2015
70. Xia Y, Chai X, Zhou C, Ren Q. Corneal nerve morphology and sensitivity changes after ultraviolet A/riboflavin treatment. *Exp Eye Res* 2011;93:541-7. <http://dx.doi.org/10.1016/j.exer.2011.06.021>
71. Pollhammer M, Cursiefen C. Bacterial keratitis early after corneal cross-linking with riboflavin and ultraviolet-A. *J Cataract Refract Surg* 2009;35:588-9. <http://dx.doi.org/10.1016/j.jcrs.2008.09.029>
72. Lange C, Böhringer D, Reinhard T. Corneal endothelial loss after cross-linking with riboflavin and ultraviolet-A. *Graefes Arch Clin Exp Ophthalmol* 2012;250:1689-91. <http://dx.doi.org/10.1007/s00417-012-2101-x>
73. Bagga B, Pahuja S, Murthy S, Sangwan VS. Endothelial failure after collagen cross-linking with riboflavin and UV-A: case report with literature review. *Cornea* 2012;31(10):1197-200. <http://dx.doi.org/10.1097/ICO.0b013e31823cbeb1>
74. Scarcelli G, Kling S, Quijano E, Pineda R, Marcos S, Yun SH, et al. Brillouin microscopy of collagen crosslinking: noncontact depth-dependent analysis of corneal elastic modulus. *Invest Ophthalmol Vis Sci* 2013;54:1418-25. <http://dx.doi.org/10.1167/iovs.12-11387>
75. Tomita M, Yoshida Y, Yamamoto Y, et al. In vivo confocal laser microscopy of morphologic changes after simultaneous LASIK and accelerated collagen crosslinking for myopia: one-year results. *J Cataract Refract Surg* 2014;40:981-90. <http://dx.doi.org/10.1016/j.jcrs.2013.10.044>
76. Mastropasqua L, Nubile M, Calienno R, et al. Corneal cross-linking: intrastromal riboflavin concentration in iontophoresis-assisted imbibition versus traditional and transepithelial techniques. *Am J Ophthalmol* 2014;157:623-630.e1. <http://dx.doi.org/10.1016/j.ajo.2013.11.018>
77. Spadea L, Salvatore S, Paroli MP, Vingolo EM. Recovery of corneal sensitivity after collagen crosslinking with and without epithelial debridement in eyes with keratoconus. *J Cataract Refract Surg* 2015. <http://dx.doi.org/10.1016/j.jcrs.2014.06.030>
78. Wasilewski D, Mello GHR, Moreira H. Impact of collagen cross-linking on corneal sensitivity in keratoconus patients. *Cornea* 2013;32:899-902. <http://dx.doi.org/10.1097/ICO.0b013e31827978c8>
79. Kymionis GD, Grentzelos MA, Portaliou DM, et al. Corneal collagen cross-linking (CXL) combined with refractive procedures for the treatment of corneal ectatic disorders: CXL plus. *J Refract Surg* 2014;30:566-76. <http://dx.doi.org/10.3928/1081597X-20140711-10>
80. Schumacher S, Oeftiger L, Mrochen M. Equivalence of biomechanical changes induced by rapid and standard corneal cross-linking, using riboflavin and ultraviolet radiation. *Invest Ophthalmol Vis Sci* 2011;52:9048-52. <http://dx.doi.org/10.1167/iovs.11-7818>
81. Krueger RR, Herekar S, Spoerl E. First proposed efficacy study of high versus standard irradiance and fractionated riboflavin/Ultraviolet A cross-linking with equivalent energy exposure. *Eye Contact Lens* 2014;40:353-7. <http://dx.doi.org/10.1097/ICL.0000000000000095>
82. Spoerl E, Huhle M, Seiler T. Induction of cross-links in corneal tissue. *Exp Eye Res* 1998;66:97-103. <http://dx.doi.org/10.1006/exer.1997.0410>