

# Corneal collagen crosslinking with riboflavin and ultraviolet A to treat induced keratectasia after laser in situ keratomileusis

Farhad Hafezi, MD, John Kanellopoulos, MD, Rainer Wiltfang, MD, Theo Seiler, MD, PhD

**PURPOSE:** To determine whether riboflavin and ultraviolet-A (UVA) corneal crosslinking can be used as an alternative therapy to prevent the progression of keratectasia.

**SETTING:** Institute for Refractive and Ophthalmic Surgery, Zurich, Switzerland, and a private clinic, Athens, Greece.

**METHODS:** Corneal crosslinking was performed in 10 patients with formerly undiagnosed forme fruste keratoconus or pellucid marginal corneal degeneration who had laser in situ keratomileusis (LASIK) for myopic astigmatism and subsequently developed iatrogenic keratectasia. Surgery was performed in 1 eye per patient.

**RESULTS:** Crosslinking induced by riboflavin and UVA arrested and/or partially reversed keratectasia over a postoperative follow-up of up to 25 months as demonstrated by preoperative and postoperative corneal topography and a reduction in maximum keratometric readings.

**CONCLUSION:** Riboflavin–UVA corneal crosslinking increased the biomechanical stability of the cornea and may thus be a therapeutic means to arrest and partially reverse the progression of LASIK-induced iatrogenic keratectasia.

*J Cataract Refract Surg 2007; 33:2035–2040 © 2007 ASCRS and ESCRS*

Since its first description in 1998, iatrogenic keratectasia induced by laser in situ keratomileusis (LASIK) was quickly recognized as a major complication of corneal refractive laser surgery.<sup>1,2</sup> Affected eyes have progressive central or inferior corneal steepening associated with stromal thinning and significant changes in refractive error. The major risk factors for keratectasia after LASIK surgery are a low residual stromal thickness (RST), retreatments, and preexisting abnormal

corneal topography.<sup>3,4</sup> Until recently, treatment options were limited. In addition to rigid contact lenses, insertion of intrastromal rings might help mechanically stabilize the cornea.<sup>5–7</sup> However, most cases are treated by penetrating keratoplasty (PKP).<sup>8</sup>

Riboflavin and ultraviolet-A (UVA) crosslinking of corneal collagen is a new method to increase the biomechanical stability of the cornea by inducing additional crosslinks between or within collagen fibers using UVA light and riboflavin as photomediators.<sup>9</sup> Its therapeutic potential for the treatment of progressive keratoconus was shown in a clinical phase I study.<sup>10</sup>

Recently, Kohlhaas et al.<sup>11</sup> reported a case of iatrogenic keratectasia after LASIK that was successfully treated by crosslinking. We report the application of this method in a series of cases with a follow-up period of up to 25 months.

## PATIENTS AND METHODS

### Patient Cohort

This study comprised 10 patients who had LASIK at different locations and were referred to 2 centers (4 to Institute

Accepted for publication July 18, 2007.

From the Institute for Refractive and Ophthalmic Surgery (Hafezi, Seiler), Zurich, Switzerland; the Department of Ophthalmology (Kanellopoulos), New York University Medical School, New York, New York, USA; and private clinics, Athens, Greece (Kanellopoulos), and Munich, Germany (Wiltfang).

No author has a financial or proprietary interest in any material or method mentioned.

Corresponding author: Farhad Hafezi, MD, Institute for Refractive and Ophthalmic Surgery, Stockerstrasse 37, CH-8002 Zurich, Switzerland. E-mail: [farhad.hafezi@iroc.ch](mailto:farhad.hafezi@iroc.ch).

**Table 1.** Preoperative and postoperative findings.

Case	Probable Reason	Before Crosslinking						
		Optical Pachy ( $\mu\text{m}$ )	Ultrasound Pachy ( $\mu\text{m}$ )	Maximum K Reading (D)	BSCVA	Sph	Cyl	Axis
1	ff PMD	610	605	57.4	20/60	1.25	-4.25	101
2	NAR	400	405	54.1	20/25	0.00	-3.50	50
3	Deep ablation	360	400	59.7	20/200	-11.00	-5.75	100
4	ff KC	410	410	52.2	20/50	-1.00	-3.00	115
5	ff KC	425	420	51.6	20/30	1.00	-3.00	123
6	ff KC	400	405	55.6	20/200	-5.00	-5.50	145
7	ff KC	420	420	57.6	20/200	-7.00	-4.00	115
8	ff KC	480	475	59.3	20/50	-2.00	-3.50	105
9	ff KC	465	470	49.6	20/200	-3.00	-5.25	75
10	ff KC	420	425	47.6	20/100	-3.50	-3.75	85

BSCVA = best spectacle-corrected visual acuity; Cyl = cylinder; ff KC = forme fruste keratoconus; ff PMD = forme fruste pellucid marginal degeneration; FU = follow-up; NAR = no apparent reason; Pachy = Pachymetry

for Refractive and Ophthalmic Surgery, Zurich, Switzerland; 6 to LaserVision, Athens, Greece). The patients were contact lens intolerant or refused to wear contact lenses. All patients had signs of progressive induced keratectasia with maximum keratometric (K) readings of 60.0 diopters (D) and a central corneal thickness (CCT) by optical and ultrasonic pachymetry of at least 400  $\mu\text{m}$ . Inclusion criteria were identification of progressive keratectasia in corneal topographies using the increase in maximum K readings in several consecutive recordings over a period of up to 3 months and changes in refraction reported by the patient, referring physician, or both. Crosslinking was performed in 1 eye of each patient.

## Examination

The preoperative and postoperative examinations included slitlamp evaluation; best spectacle-corrected visual acuity (BSCVA) with and without pinhole; corneal topography and Scheimpflug imaging, including corneal thickness at the thinnest point (Pentacam, Oculus Instruments); ultrasonic pachymetry (Tomey) of the central cornea; and Goldmann applanation tonometry. Three consecutive measurements were taken for corneal topography, Scheimpflug analysis, and pachymetry. For corneal topography, the measurement with the highest K value was chosen and for ultrasound pachymetry, the thinnest measurement was chosen. (Each single measurement represents the mean of 5 consecutive measurements.)

## Surgical Technique

The surgical technique has been described.<sup>10</sup> After topical anesthesia of tetracaine 1% and oxybuprocaine 0.4% eye-drops was administered, the corneal epithelium was mechanically removed within a 8.0 mm diameter exclusively.

Next, riboflavin (0.1% solution 10 mg riboflavin-5-phosphate in 10 mL dextran-T-500 20% solution) was applied every 3 minutes for approximately 30 minutes until the stroma was completely penetrated and aqueous was stained yellow (riboflavin shielding). Ultraviolet-A irradiation was accomplished using a commercially available UVA system (UV-X, Peschke Meditrad) with Koehler optics. Before treatment,

the intended 3 mW/cm<sup>2</sup> surface irradiance (5.4 J/cm<sup>2</sup> surface dose after 30 minutes) was calibrated using a UVA meter (LaserMate-Q, LASER 2000) at a working distance of 10 cm. During treatment, riboflavin solution was applied every 5 minutes to ensure saturation and balanced salt solution (BSS) was applied every 2 minutes to moisten the cornea.

After the treatment, a contact lens (Acuvue, Johnson & Johnson) soaked in preservative-free ofloxacin 0.3% (Floxal SDU) was applied for 72 hours until the epithelium completely healed. This was followed by application of fluoro-metholone 0.1% eyedrops (FML Liquifilm) twice daily for 6 weeks.

## RESULTS

Four patients were men, and 6 were women. The mean age was 36.2 years (range 27 to 43 years).

Table 1 shows the preoperative and postoperative findings in all patients. The reason for the biomechanical instability after LASIK was formerly undiagnosed forme fruste keratoconus in 7 cases, undiagnosed pellucid marginal degeneration (PMD) in 1 case, and high correction with a residual corneal thickness of 360  $\mu\text{m}$  in 1 case; the cause could not be identified in 1 patient.

The surgery and postoperative period were uneventful except in 1 case, in which there was endothelial irregularity and some endothelial opacity. The endothelium cleared and had a normal cell count (2350 cells/mm<sup>2</sup>) 12 months after crosslinking. In the early postoperative period, all eyes had corneal haze comparable to the subepithelial haze after photorefractive keratectomy. The haze was not subepithelial, however. Rather, it was visible in the anterior stroma up to 80% of stromal thickness. Twelve months after crosslinking, all corneas were clear.

Preoperatively, the CCT determined by Pentacam was virtually identical to the ultrasound readings.

**Table 1** (Cont.)

Fu (Mo)	After Crosslinking						
	Optical Pachy ( $\mu\text{m}$ )	Ultrasound Pachy ( $\mu\text{m}$ )	Maximum K Reading (D)	BSCVA	Sph	Cyl	Axis
25	600	610	56.3	20/25	1.25	−2.3	100
12	385	410	49.6	20/20	0	−1.0	60
12	350	410	57.3	20/100	−8	−4.0	110
12	400	420	50.2	20/30	−1	−2.5	110
17	400	440	48.8	20/30	0.5	−1.5	115
21	410	400	53.9	20/40	−4	−3.5	155
20	410	430	55.6	20/50	−5.5	−3.4	110
25	460	500	59.1	20/25	−1.75	−2.3	115
23	450	480	48.3	20/50	−3.75	−3.3	80
17	420	440	47.1	20/25	−3.75	−2.3	85

Postoperatively, optical pachymetry yielded smaller values than ultrasound pachymetry.

In most cases, BSCVA improved, cylinder decreased, and the corneal optics were more regular. In all cases, there was a reduction in the maximum K readings 12 months after crosslinking. Based on the poor reproducibility of the maximum K readings, a difference between preoperative and postoperative values of 2.0 D or more was considered clinically meaningful, which was the case in 5 of the 10 eyes.

### Case Reports

Following are 2 case reports. In Case 1, LASIK iatrogenic keratectasia developed after LASIK in an eye with preoperatively unrecognized forme fruste or slowly progressive PMD. In Case 2, bilateral keratectasia occurred after LASIK in an eye without an apparent preoperative ectatic disorder.

**Case 1** A 32-year-old man presented in 2004 with a history of LASIK in the left eye for myopic astigmatism in April 2003. The initial central corneal pachymetry in that eye was 617  $\mu\text{m}$ , the uncorrected visual acuity (UCVA) was 20/60, and the BSCVA was 20/16 with  $-2.50 -0.75 \times 82$ . Corneal topography (axial representation) showed signs of forme fruste PMD that was not recognized by the surgeon at that time (Figure 1, A). On the first postoperative day, vision was markedly decreased and the patient decided to postpone surgery in the fellow eye.

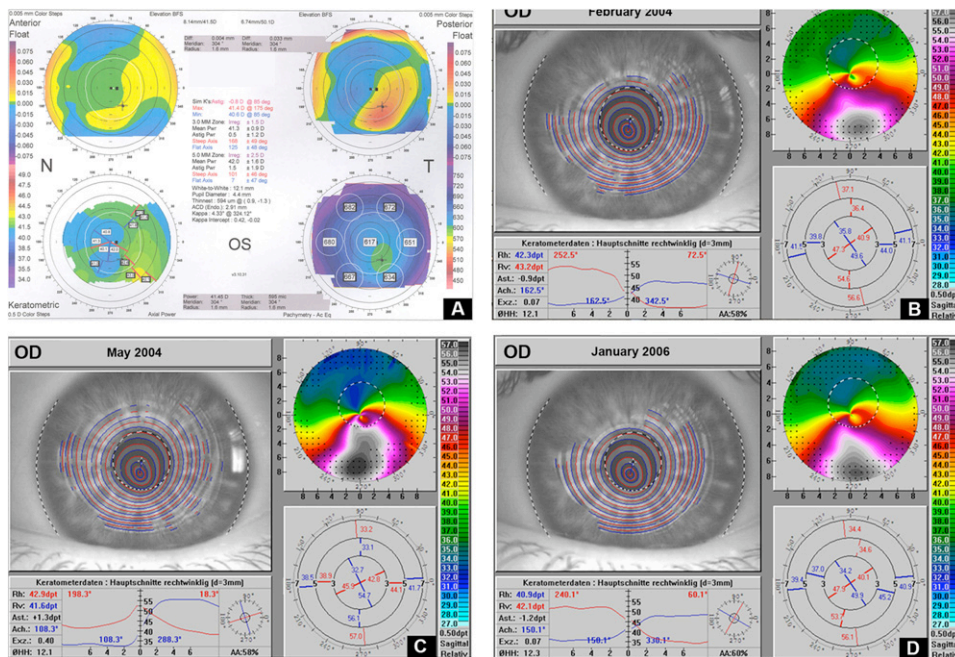
At the initial examination at presentation in February 2004, 10 months after the primary surgery, the left eye had a UCVA of 20/400, a BSCVA of 20/60, and corneal thickness of 610  $\mu\text{m}$ . Slitlamp examination revealed a normal state after LASIK. Corneal topography

showed a decentered ablation with marked inferior steepening (maximum K reading 55.5 D) consistent with the diagnosis of iatrogenic keratectasia after LASIK (Figure 1, B).

Over the following 3 months, distinct progression of keratectasia was observed in the left eye. The maximum K reading was 57.40 D in May 2004 (Figure 1, C). As PKP was the only valuable therapeutic alternative, the patient was offered riboflavin-UVA crosslinking as a treatment option. Informed consent was obtained after the nature of the procedure and its known risks were explained. During the 25 months after treatment, corneal topography of the left eye showed continuous regression of the maximum K readings (Figures 1, D, and 2). The BSCVA 25 months after treatment was 20/25.

**Case 2** Bilateral keratectasia (Figure 3, A and C) developed 1 year after LASIK with slow progression in both eyes. Crosslinking was performed in the left, nondominant eye. Preoperative CCT by ultrasonic pachymetry was 400  $\mu\text{m}$ . Two weeks after treatment, localized endothelial damage of approximately 0.75 mm  $\times$  0.75 mm was noted, along with stromal edema in the central deep cornea exactly below the corneal apex, corresponding to the area of the greatest steepness. The stromal edema slowly resolved during the following 6 weeks. Seven months after treatment, corneal topography of the left eye showed a significant decrease in central corneal steepening (Figure 3, D); corneal steepening remained unchanged in the right eye (Figure 3, B). At 9 months, the central irregular endothelium had cleared and the endothelial cell count was 2350 cells/ $\text{mm}^2$  with mild polymorphism. A preoperative endothelial cell count was not available in





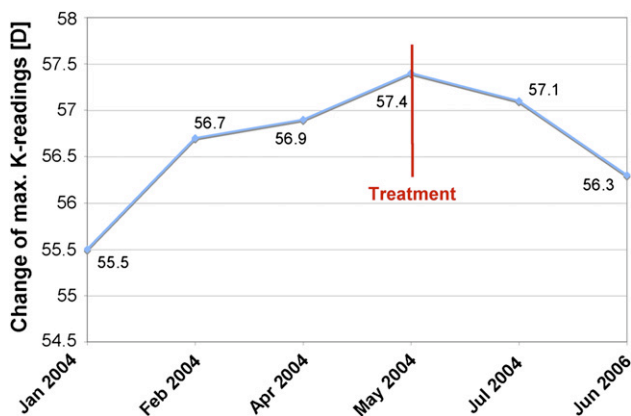
**Figure 1.** Time course of corneal topographies (axial representation) A: Before LASIK. B: Ten months after LASIK. C: Thirteen months after LASIK, 1 day before riboflavin-UVA crosslinking. D: Twenty-five months after crosslinking, the maximum steepening of the inferior cornea is significantly decreased.

this case, and the endothelial cell count in the fellow eye was 2600 cells/mm<sup>2</sup>.

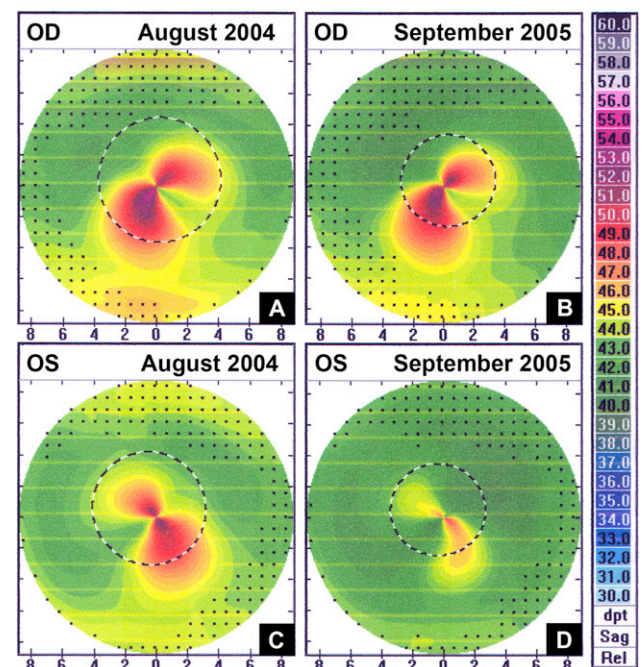
## DISCUSSION

Although LASIK has become increasingly safe and predictable in the past 10 years, induced keratectasia remains a rare but serious complication for which the underlying reasons are not fully understood. Therefore, a new therapeutic means to handle a complication of such severity after elective surgery would be beneficial. Clearly, prevention of induced keratectasia is the better strategy and special emphasis should be

placed on recognizing corneas that are at risk before surgery. Reduction of corneal biomechanical strength seems to be an essential element in the chain of events leading to iatrogenic keratectasia after LASIK.



**Figure 2.** Change in maximal K readings. After LASIK, induced keratectasia occurred with progressive increase in the maximum K readings from 55.5 D to 57.4 D until May 2004, the date of crosslinking treatment. The maximum K readings decreased to 56.3 D at 25 months after crosslinking.



**Figure 3.** Bilateral iatrogenic keratectasia after LASIK. A: Right cornea with iatrogenic keratectasia 12 months after LASIK. B: The right cornea is topographically unchanged 25 months after LASIK. C: The left cornea 12 months after LASIK. D: The left cornea 13 months after crosslinking shows a significant distinct decrease in keratectasia.

The anterior stroma confers more biomechanical strength to the cornea than the posterior stroma, and it is the anterior stroma that is weakened by flap generation and tissue ablation in LASIK surgery (Park D, et al. IOVS 1995; 36:ARVO Abstract 186). It would therefore be of great clinical value to have a tool to determine the individual biomechanical strength of a cornea preoperatively. Such a tool would enable us to detect corneas at risk preoperatively. Unfortunately, such a technique is not available; however, promising approaches are being studied. These include determination of corneal hysteresis using an ocular response analyzer or interferometric measurements.<sup>12,13</sup>

Several factors and coefficients can be used to determine the extent of keratectasia. To document progression or regression, parameters such as elevation maps (ie, the so-called anterior or posterior float) would be a valuable alternative. However, preoperative Scheimpflug analysis was not available for most of our patients because the initial LASIK procedure was performed years ago when Scheimpflug imaging was rarely available. In contrast, the maximum K reading is a parameter that is easily accessible to all corneal surgeons because topography measurements have been routinely available for many years. Therefore, and in view of the distinct reduction of ectasia in the cases presented here, we believe that maximum K readings are a valuable tool in characterizing keratectasia, although the reproducibility of this parameter is limited. To improve reproducibility, we performed 3 measurements and chose the highest of the 3 maximum K readings.

Our results show that riboflavin-UVA corneal crosslinking can arrest and, in some cases, partially reverse otherwise progressive iatrogenic keratectasia after LASIK. The observed reduction in maximum K values was probably the result of the increased biomechanical stability of the cornea after crosslinking and is in line with findings in primary keratoconus patients treated similarly.<sup>10</sup> After crosslinking in primary keratoconus, Caporossi et al.<sup>14</sup> found a trend toward a more regular cornea that is accompanied by an increase in BSCVA. This effect was also found in our patients, but to a larger degree. Four of the 10 eyes gained more than 2 lines in the BSCVA. The cause of this optical regularization is unknown.

Metalloproteinases and other enzymes involved in inflammatory processes may play a role in the pathogenesis of keratoconus.<sup>15</sup> It has not been shown that these components also play a role in iatrogenic keratectasia. One might speculate that crosslinking-induced inflammation, including enzymatic degradation of collagen, leads to deterioration. On the other hand, Spoerl et al.<sup>16</sup> report that crosslinked collagen is significantly more resistant to enzymatic degradation

than native corneal collagen. Perhaps the biochemical stabilization of collagen by crosslinking contributes to the effect.

Our preliminary results show at least middle-term efficacy of the technique. Twelve months after crosslinking, the preoperatively progressive keratectasia was halted ( $n = 5$ ) or had regressed ( $n = 5$ ). However, as with any new surgical technique, safety is a concern.

Spoerl et al.<sup>17</sup> clearly show that the UVA intensity used during crosslinking is far below the damage threshold for the corneal endothelium, iris, lens, and retina. The structures at greatest risk for damage from the induced radicals are the keratocytes and corneal endothelium. Indeed, keratocytes show apoptosis after crosslinking as deep as 320  $\mu\text{m}$ .<sup>18</sup> As long as the corneal stroma is at least 400  $\mu\text{m}$  thick and the irradiance is 3  $\text{mW}/\text{cm}^2$  or less, the endothelium is protected by the riboflavin concentration in the stroma (riboflavin shielding).<sup>17</sup> Hot spots in the illumination area or corneas that are too thin may risk damage to the endothelium.

In Case 2, where localized endothelial damage after crosslinking was observed, CCT was 400  $\mu\text{m}$  including the epithelium. Stromal thickness may have been as low as 350  $\mu\text{m}$ , thus too thin to protect the endothelium. In retrospect, it would have been better to increase stromal thickness to 400  $\mu\text{m}$  by swelling using riboflavin solution without dextran after epithelium debridement.

A major factor predisposing to LASIK-induced keratectasia is unrecognized thinning corneal disorders such as keratoconus or PMD, including forme fruste and early stage. In both conditions, altered collagen orientation and structure decrease the biomechanical strength of the tissue.<sup>19,20</sup> There is general agreement that corneal thinning disorders are a contraindication to LASIK.<sup>1</sup> Although various indices to detect ectatic disorders in corneal topography have been proposed,<sup>21,22</sup> identification of forme fruste keratoconus or PMD remains difficult in some cases.

Other factors include retreatments, thin corneas, and a low RST caused by generation of thick flaps or excessive tissue ablation.<sup>3,4,23-26</sup> Some authors suggest that an absolute RST of at least 250  $\mu\text{m}$  should always be respected; others suggest that the risk for ectasia occurs when the ablation reduces corneal thickness to 55% or more of the preoperative values<sup>1,2,23,24</sup> or that the minimum corneal thickness might be specific to the individual eye.<sup>3</sup> In some cases of iatrogenic keratectasia, even postoperative cases, the reason for the keratectasia remains unclear and we must assume decreased, but asymptomatic, biomechanical strength, as we describe in Case 2.

The treatment of iatrogenic keratectasia after LASIK has been rigid contact lenses and if contact lenses are

not tolerated or the ectatic process is progressive, penetrating or deep lamellar keratoplasty. At this stage of clinical knowledge about corneal crosslinking, we recommend using it as a minimally invasive alternative to keratoplasty in patients who are contact lens-intolerant. After crosslinking, penetrating or deep lamellar keratoplasty remains a therapeutic option. In this paper, we show the feasibility of corneal crosslinking to arrest progressive keratectasia after LASIK surgery. After more clinical information on the safety and efficacy of the method is available, the strategy may change significantly. Under such circumstances, crosslinking might be performed as early as possible to prevent a further decrease in BSCVA.

In conclusion, riboflavin-UVA corneal crosslinking increased the biomechanical and biochemical stability of the cornea and may thus be a therapeutic means to arrest or reverse the progression of LASIK-induced keratectasia. It is common clinical knowledge that keratoconus progresses independent of whether rigid contact lenses are used. Similarly, to our knowledge, no scientific information is available on whether rigid contact lenses can arrest iatrogenic keratectasia after LASIK. Although we included only contact lens-intolerant patients in our study, based on our findings, we believe crosslinking should be performed in all patients with progressive iatrogenic keratectasia, even if they can tolerate contact lenses. Further studies should include more patients and a longer follow-up to verify the permanency of the induced effects as well as the safety of crosslinking.

## REFERENCES

- Seiler T, Quirke AW. Iatrogenic keratectasia after LASIK in a case of forme fruste keratoconus. *J Cataract Refract Surg* 1998; 24:1007–1009
- Seiler T, Koufala K, Richter G. Iatrogenic keratectasia after laser in situ keratomileusis. *J Refract Surg* 1998; 14:312–317
- Binder PS. Ectasia after laser in situ keratomileusis. *J Cataract Refract Surg* 2003; 29:2419–2429
- Randleman JB, Russell B, Ward MA, et al. Risk factors and prognosis for corneal ectasia after LASIK. *Ophthalmology* 2003; 110:267–275
- Kymionis GD, Siganos CS, Kounis G, et al. Management of post-LASIK corneal ectasia with Intacs inserts; one-year results. *Arch Ophthalmol* 2003; 121:322–326
- Lovisolo CF, Fleming JF. Intracorneal ring segments for iatrogenic keratectasia after laser in situ keratomileusis or photorefractive keratectomy. *J Refract Surg* 2002; 18:535–541
- Siganos CS, Kymionis GD, Astyrakakis N, Pallikaris IG. Management of corneal ectasia after laser in situ keratomileusis with INTACS. *J Refract Surg* 2002; 18:43–46
- Seitz B, Rozsival P, Feuermannova A, et al. Penetrating keratoplasty for iatrogenic keratoconus after repeat myopic laser in situ keratomileusis: histological findings and literature review. *J Cataract Refract Surg* 2003; 29:2217–2224
- Spoerl E, Seiler T. Techniques for stiffening the cornea. *J Refract Surg* 1999; 15:711–713
- Wollensak G, Spoerl E, Seiler T. Riboflavin/ultraviolet-A-induced collagen crosslinking for the treatment of keratoconus. *Am J Ophthalmol* 2003; 135:620–627
- Kohlhaas M, Spoerl E, Speck A, et al. Eine neue Behandlung der Keratektasie nach LASIK durch Kollagenvernetzung mit Riboflavin/UVA-Licht. [A new treatment of keratectasia after LASIK with riboflavin/UVA light cross-linking]. *Klin Monatsbl Augenheilkd* 2005; 222:430–436
- Jaycock PD, Lobo L, Ibrahim J, et al. Interferometric technique to measure biomechanical changes in the cornea induced by refractive surgery. *J Cataract Refract Surg* 2005; 31:175–184
- Luce DA. Determining in vivo biomechanical properties of the cornea with an ocular response analyzer. *J Cataract Refract Surg* 2005; 31:156–162
- Caporossi A, Baiocchi S, Mazzotta C, et al. Parasurgical therapy for keratoconus by riboflavin-ultraviolet type A rays induced cross-linking of corneal collagen; preliminary refractive results in an Italian study. *J Cataract Refract Surg* 2006; 32:837–845
- Rehany U, Lahav M, Shoshan S. Collagenolytic activity in keratoconus. *Ann Ophthalmol* 1982; 14:751–754
- Spoerl E, Wollensak G, Seiler T. Increased resistance of cross-linked cornea against enzymatic digestion. *Curr Eye Res* 2004; 29:35–40
- Spoerl E, Mrochen M, Sliney D, et al. Safety of UVA-riboflavin cross-linking of the cornea. *Cornea* 2007; 26:385–389
- Mazzotta C, Balestrazzi A, Traversi C, et al. Treatment of progressive keratoconus by riboflavin-UVA-induced cross-linking of corneal collagen; ultrastructural analysis by Heidelberg Retinal Tomograph II in vivo confocal microscopy in humans. *Cornea* 2007; 26:390–397
- Rodrigues MM, Newsome DA, Krachmer JH, Eiferman RA. Pelucid marginal corneal degeneration: a clinicopathologic study of two cases. *Exp Eye Res* 1981; 33:277–288
- Meek KM, Tuft SJ, Huang Y, et al. Changes in collagen orientation and distribution in keratoconus corneas. *Invest Ophthalmol Vis Sci* 2005; 46:1948–1956
- Schwiegerling J, Greivenkamp JE. Keratoconus detection based on videokeratoscopic height data. *Optom Vis Sci* 1996; 73:721–728
- Rabinowitz YS. Videokeratographic indices to aid in screening for keratoconus. *J Refract Surg* 1995; 11:371–379
- Seiler T. Iatrogenic keratectasia: academic anxiety or serious risk? [guest editorial] *J Cataract Refract Surg* 1999; 25:1307–1308
- Kohnen T. Iatrogenic keratectasia: current knowledge, current measurements [editorial]. *J Cataract Refract Surg* 2002; 28:2065–2066
- Koch DD. The riddle of iatrogenic keratectasia [editorial]. *J Cataract Refract Surg* 1999; 25:453–454
- Comaish IF, Lawless MA. Progressive post-LASIK keratectasia: biomechanical instability or chronic disease process? *J Cataract Refract Surg* 2002; 28:2206–2213



First author:

Farhad Hafezi, MD

Institute for Refractive and Ophthalmic Surgery, Zurich, Switzerland