

Pregnancy May Trigger Late Onset of Keratectasia After LASIK

To the Editor:

It is common knowledge that the biomechanical stability of connective tissue changes during pregnancy, leading to reduced stiffness and increased extensibility. These changes are most probably hormone-induced and, therefore, corneal biomechanics also may change during pregnancy.

Five patients who underwent LASIK experienced vision deterioration during pregnancy, which we attribute to iatrogenic keratectasia although the cornea prior to pregnancy was stable for years. All patients except one were primipara. All patients showed progressive keratectasia and received corneal collagen cross-linking (CXL) to stop progression.¹ Patient age and time of onset of iatrogenic keratectasia are shown in the Table.

Representative case: A 32-year-old woman underwent bilateral LASIK in Turkey for -5.00 diopters (D) in the right eye and -4.50 D in the left eye in 2002. Preoperative topography is shown in the Figure. According to the patient, the surgeon stated that uncorrected distance visual acuity (UDVA) was 20/20 in both eyes at 6-month follow-up. Postoperative UDVA remained stable for 6 years until her seventh month of pregnancy in July 2008. Scheimpflug analysis showed keratectasia in the right eye with K_{\max} values of 51.60 D and a minimal corneal thickness of 359 μm , compared to 45.30 D and 398 μm and normal topography in the left eye.

Our results suggest that, aside from misinterpretation of preoperative topography and low residual stromal thickness, additional factors may induce iatrogenic keratectasia under certain circumstances.

TABLE

Late-onset Iatrogenic Keratectasia After LASIK in Pregnant Women

Patient No.	Age at LASIK (y)	Age at Onset (y)	Occurrence After LASIK (y)
1	28	32	4
2	32	38	6
3	27	32	5
4	33	37	4
5	31	40	9

We cannot rule out that some of the cases could have had a preexisting minimal corneal thickness at the lower end of the normal distribution (ie, 505 μm), a minor asymmetry and elevation at the posterior pole (ie, 12 μm at a reference sphere of 8 mm), or even keratoconus. These corneas might have been borderline compensated and biomechanically stable until an additional factor arose, eg, the increase in serum estrogen levels during pregnancy. This may explain why ectasia occurred up to 9 years after LASIK concomitant with pregnancy.

Only a few cases of iatrogenic keratectasia and keratoconus occurring during pregnancy have been reported, with one included in this series.^{2,3} There is growing evidence that the massive estrogen increase in late pregnancy not only prepares the female body for birth but may also increase the risk of keratectasia in predisposed individuals. Suzuki et al⁴ identified estrogen receptors in the human cornea, and Spoerl et al⁵ have demonstrated that ex vivo porcine corneas show a distinct reduction in biomechanical stiffness when ex-

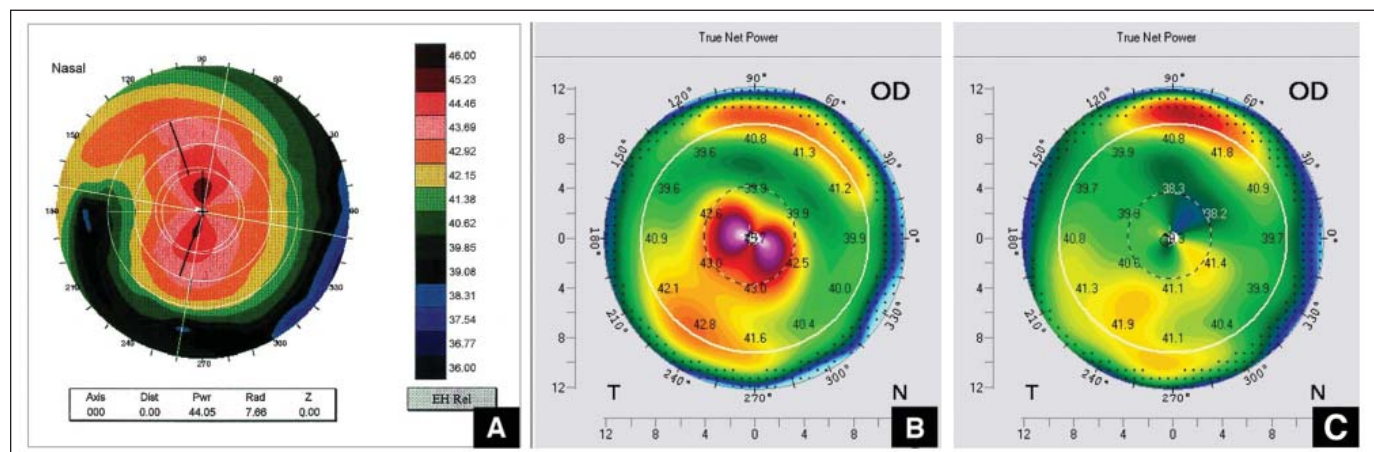


Figure. Corneal topographies of unilateral central keratectasia. **A)** Preoperative topography shows no signs of keratectasia on the anterior corneal surface. **B)** Eight years after LASIK and 1 year after delivery, central keratectasia is noted. **C)** Twelve months after subsequent cross-linking, significant regression occurred.

posed to high doses of estradiol. Aside from estrogen, other hormones such as cortisol and thyroxin show substantial changes during pregnancy and may also alter corneal biomechanics.⁶

Borderline corneas with the risk of developing keratectasia during pregnancy need to be identified preoperatively and the Ectasia Risk Score System (ERSS) may help characterize such biomechanical configurations.⁷ Because of the limited preoperative data, correct application of the ERSS in the patients presented herein was not possible, but at least 2 patients were at moderate risk (ERSS >2) preoperatively. Based on only five cases, a general recommendation to consider future pregnancy a potential risk factor of LASIK is not appropriate; however, in our clinics the counseling of LASIK in female patients younger than 40 years with an ERSS ≥ 2 will include the additional risk during pregnancy.

Future systematic studies should investigate the effect of pregnancy on corneal biomechanics. Pregnancy may stimulate progression of corneal keratectasia years after LASIK. This risk should be included in the benefit-risk analysis prior to LASIK in borderline cases.

Farhad Hafezi, MD, PhD
Geneva, Switzerland
Tobias Koller, MD
Victor Derhartunian, MD
Theo Seiler, MD, PhD
Zurich, Switzerland

The authors have no financial interest in the materials presented herein.

REFERENCES

1. Hafezi F, Kanellopoulos J, Wiltfang R, Seiler T. Corneal collagen cross-linking with riboflavin and ultraviolet A to treat induced keratectasia after laser in situ keratomileusis. *J Cataract Refract Surg*. 2007;33(12):2035-2040.
2. Hafezi F, Iseli HP. Pregnancy-related exacerbation of iatrogenic keratectasia despite corneal collagen crosslinking. *J Cataract Refract Surg*. 2008;34(7):1219-1221.
3. Padmanabhan P, Radhakrishnan A, Natarajan R. Pregnancy-triggered iatrogenic (post-laser in situ keratomileusis) corneal ectasia—a case report. *Cornea*. 2010;29(5):569-572.
4. Suzuki T, Kinoshita Y, Tachibana M, et al. Expression of sex steroid hormone receptors in human cornea. *Curr Eye Res*. 2001;22(1):22-33.
5. Spoerl E, Zubaty V, Terai N, Pillunat LE, Raiskup F. Influence of high-dose cortisol on the biomechanics of incubated porcine corneal strips. *J Refract Surg*. 2009;25(9):S794-S798.
6. Gatziofias Z, Thanos S. Acute keratoconus induced by hypothyroxinemia during pregnancy. *J Endocrinol Invest*. 2008;31(3):262-266.
7. Randleman JB, Woodward M, Lynn MJ, Stulting RD. Risk assessment for ectasia after corneal refractive surgery. *Ophthalmology*. 2008;115(1):37-50.

Interface Fluid Syndrome Associated With Cataract Surgery

To the Editor:

Interface fluid syndrome (IFS) is a flap-related complication of LASIK surgery, first reported in the literature by Lyle and Jin in 1999.¹ Symptoms usually appear 1 week to 2 months after uncomplicated LASIK. Clinically, it is associated with diffuse, nongranular haze or a distinct fluid-filled cleft in the LASIK interface wound confined to the central and paracentral areas usually caused by steroid-inducing ocular hypertension.^{1,2} Differential diagnosis with diffuse lamellar keratitis is warranted.

Interface fluid syndrome has also been reported to be caused by uveitis,³ vitreoretinal surgery,⁴ or decreased endothelial cell density. It results in transudation of aqueous humor across the corneal endothelium and stromal lamellae of the residual stromal bed with subsequent fluid accumulation and swelling in the hypocoelular primitive LASIK wound.⁵

Interface fluid syndrome after cataract surgery without associated endothelial cell dysfunction has not been reported previously.

A 47-year-old man underwent bilateral LASIK for low myopia without complications. Uncorrected distance visual acuity (UDVA) 1 year after surgery was 20/20 in both eyes.

Three years after surgery, the patient presented with glare and bad adaptation to darkness. On examination, posterior subcapsular cataracts +3 were noted in the right eye.

Phacoemulsification with in-the-bag intraocular lens (IOL) implantation (18.50 D, double-K SRK/T) was performed in the right eye. One day after surgery, he reported blurred vision, pain, and photophobia. Clinically, he presented with paracentral nongranular haze in the interface wound concordant with stage II IFS (Fig).⁵ Central applanation intraocular pressure (IOP) was 18 mmHg, but peripheral to the LASIK flap, IOP was 38 mmHg. Viscoelastic material retained in the eye was the presumed etiology of the high IOP. After anterior chamber drainage (expression of the posterior lip of the cataract wound), IOP decreased to 16 mmHg, and topical hypotensive drugs were instilled the following day. Two days later, anterior chamber drainage of IFS was resolved (see Fig), with a final UDVA of 20/20 in the right eye.

This case documenting interface fluid collection and flap edema represents the first reported case of IFS after raised IOP following cataract surgery.

Viscoelastic material such as hyaluronate retained in the eye after cataract surgery is frequently responsible for postoperative IOP elevation.

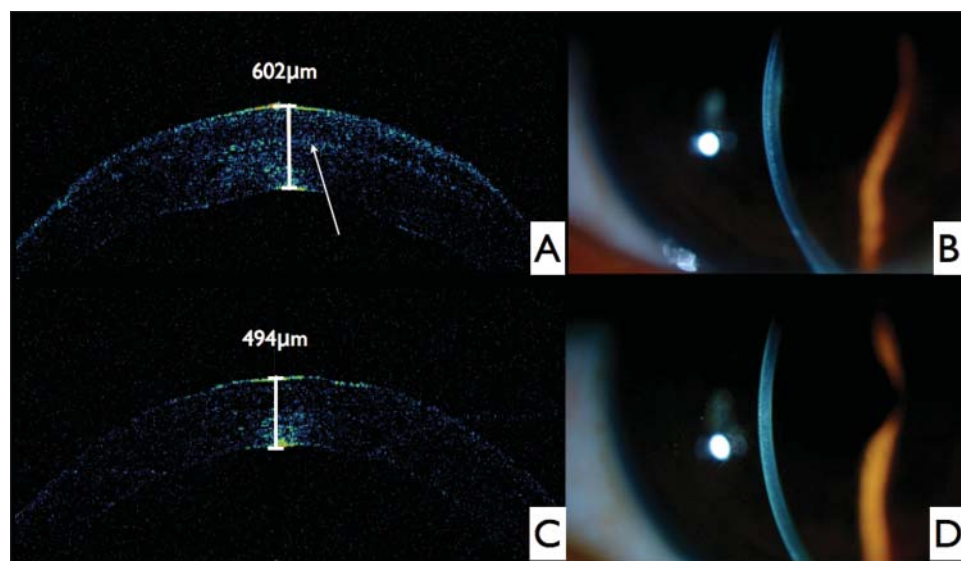


Figure. **A)** Corneal optical coherence tomography (OCT) showing fluid accumulation in the flap–stroma interface with optical pachymetry of 602 μm . The arrow indicates the interface wound. **B)** Slit-lamp examination shows corneal edema with paracentral nongranular haze concordant with stage II interface fluid syndrome. **C)** Corneal OCT shows resolution of the condition with optical pachymetry of 494 μm . **D)** Slit-lamp examination shows resolution of the corneal edema and haze.

Any condition that increases IOP is a potential cause of IFS. Interface fluid syndrome may even appear years after LASIK surgery. Interface fluid syndrome most commonly presents 1 week to a few months after surgery in steroid responsive patients. In this case, IFS occurred 3 years after LASIK. There are some reports of IFS occurring 4 years after LASIK.

To avoid missing intraocular hypertension that could lead to permanent glaucoma-related damage, it is essential to obtain accurate IOP readings peripheral to the LASIK flap.³

Previous histopathologic and ultrastructural studies on human corneas with LASIK surgery have shown that LASIK interface wounds heal in a limited and incomplete fashion,⁵ making these wounds susceptible to flap-related complications such as IFS years after LASIK.

Ophthalmologists should be aware that any condition that increases IOP or damages endothelial cell function years after LASIK may precipitate IFS. Strict removal of viscoelastic material is warranted.

Ester Carreño, MD
Alejandro Portero, MD
David J. Galarreta, MD, PhD
Valladolid, Spain
Jesús M. Merayo, MD, PhD
Oviedo, Spain

The authors have no financial or proprietary interests in the materials presented herein.

REFERENCES

1. Lyle WA, Jin GJ. Interface fluid associated with diffuse lamellar keratitis and epithelial ingrowth after laser in situ keratomileusis. *J Cataract Refract Surg*. 1999;25(7):1009-1012.
2. Hamilton DR, Manche EE, Rich LF, Maloney RK. Steroid-induced glaucoma after laser in situ keratomileusis associated with interface fluid. *Ophthalmology*. 2002;109(4):659-665.
3. McLeod SD, Mather R, Hwang DG, Margolis TP. Uveitis-associated flap edema and lamellar interface fluid collection after LASIK. *Am J Ophthalmol*. 2005;139(6):1137-1139.
4. Senthil S, Rathi V, Garudadri C. Misleading Goldmann applanation tonometry in a post-LASIK eye with interface fluid syndrome. *Indian J Ophthalmol*. 2010;58(4):333-335.
5. Dawson DG, Schmack I, Holley GP, Waring GO III, Grossniklaus HE, Edelhauser HF. Interface fluid syndrome in human eye bank corneas after LASIK: causes and pathogenesis. *Ophthalmology*. 2007;114(10):1848-1859.

doi:10.3928/1081597X-20120308-01